

## Effect of pesticide bendiocarbamate on distribution of acetylcholine- and butyrylcholine-positive nerves in rabbit's thymus

F. Dorko,<sup>1,2</sup> J. Danko,<sup>3</sup> S. Flešárová,<sup>3</sup>  
E. Boroš,<sup>4</sup> A. Sobeková<sup>5</sup>

<sup>1</sup>Institute of Anatomy, Faculty of Medicine, Pavol Jozef Šafárik University, Košice, Slovakia; <sup>2</sup>Institute of Anatomy, Faculty of Medicine, University of Ostrava, Czech Republik;

<sup>3</sup>Institute of Anatomy, University of Veterinary Medicine, Košice, Slovakia;

<sup>4</sup>Department of Surgery, Railways Hospital, Košice, Slovakia; <sup>5</sup>Institute of Pharmaceutical and Medical Chemistry, University of Veterinary Medicine, Košice, Slovakia

### Abstract

Many pesticides used in agriculture have a negative effect on organisms. The group of hazardous pesticides includes the cholinesterase inhibitor bendiocarbamate. According to literature, bendiocarbamate has relatively low toxicity in mammals and vertebrates in general, since it does accumulate in their tissues and the cholinesterase activity returns to norm within 24 h after acute exposure. The present study focused on the influence of bendiocarbamate on rabbit thymus after its administration at a dose of 5 mg/kg body weight (BW) for the period of 3 months. The thymus was observed for acetylcholinesterase (AChE) and butyrylcholinesterase (BuChE)-positive nerve fibers visualized by histochemical methods. Microscopic findings of BuChE - positive nerve fibers show the same density and the topography by the experimental and the control animals. On the other hand, AChE - positive nerve fibers in experimental animals after administration of bendiocarbamate is only poorly identified, suggesting that bendiocarbamate inhibits AChE but not BuChE.

### Introduction

Recently, a large amount of chemicals are produced, which come into close contact with the human body. Agrochemicals are a certain part of modern agro-technical procedures despite the fact that a great number of them

are on the list of risk substances. Many agrochemicals have toxic and genotoxic effects and, subsequently, after cumulative somatic mutations, also carcinogenic effects.<sup>1</sup> Uncontrolled and thoughtless use of various pesticides resulted in health problems involving nervous, endocrine, reproductive and immune systems of animals and humans. Although some pesticides have been restricted or banned because they pose risks of cancer, birth defects, or neurological damage, little attention has so far been given to what may be their greatest health risk: impairment of the immune system.<sup>2</sup> Hundreds of experimental studies on human cell cultures and animal models provide strong evidence that many pesticides are immunotoxic and may affect immune status and function.<sup>3,4</sup>

A range of pesticides belongs to the group of cholinesterase inhibitors involved in morphogenesis. Cholinesterase inhibitors are a group of chemical substances precluding hydrolysis of acetylcholine and thus causing accumulation of acetylcholine in reactive sites of live organisms. Inhibition of brain acetylcholinesterase has been the major therapeutic target for Alzheimer disease and other patients with dementia.<sup>5,6</sup> One of the cholinesterase inhibitors, bendiocarbamate, is used to control insect populations. Bendiocarbamate (2,3-isopropylatedendioxiphenyl methylcarbamate) is a pesticide acting upon invertebrates by irreversibly blocking the activity of the enzyme cholinesterase, which is critical in allowing muscle relaxation by removing the neuromuscular mediator acetylcholine.<sup>7</sup> It has relatively low toxicity in mammals and vertebrates in general, since it does accumulate in their tissues and the cholinesterase activity returns to norm within 24 h after acute exposure.<sup>8</sup> The clinical picture of bendiocarbamate intoxication includes diarrhoea, vomiting, dehydration, loss of weight, alopecia, hypersalivation and muscle tremor. Many studies proved that bendiocarbamate increases incidence of lymphoreticular tumours, such as lymphosarcomas, reticulosarcomas, lymphoid and myeloid leukaemia. Presently, the acute oral toxic dose for adult experimental animals is as follows: rat 34-156 mg/kg body weight (BW), rabbit 35-40 mg/kg BW and guinea pig 35 mg/kg BB.<sup>9</sup>

The thymus is a central lymphoid organ with an important endocrine function. It is a place where the T cells precursors proliferate and mature, these are responsible for the cell-mediated immunity. The main role of thymus-derived lymphocytes is the protection against the tumourous cells, intracellular parasites and viruses; through cytokine secretion they activate other cells of the immune system.<sup>10-13</sup> During the prenatal and postnatal period, pathological involution of the thymus may

Correspondence: Prof. František Dorko, Institute of Anatomy, Faculty of Medicine, Pavol Jozef Šafárik University in Košice, Šrobárova Street 2, Košice, Slovakia.  
Tel. +421.55.6428151 - Fax: +421.55.6428151.  
E-mail: frantisek.dorko@upjs.sk

Key words: bendiocarbamate, rabbit, thymus, histochemistry, nerve fibers.

Acknowledgements: this study was supported by the Grant of Slovak Ministry of Education No. VEGA 2/0021/09.

Received for publication: 16 May 2011.

Accepted for publication: 10 August 2011.

This work is licensed under a Creative Commons Attribution NonCommercial 3.0 License (CC BY-NC 3.0).

©Copyright F. Dorko et al., 2011  
Licensee PAGEPress, Italy  
European Journal of Histochemistry 2011; 55:e37  
doi:10.4081/ejh.2011.e37

occur in response to any form of acute stress. It may be associated with environmental toxicants, trauma, severe infection, chemotherapy, smoking, hormonal therapy or malnutrition. Not all factors influencing the size and function of thymus are known.<sup>14-17</sup>

Animal cholinesterases are widespread enzymes present in cholinergic and non-cholinergic tissues as well as in their plasma and other body fluids. They are divided into two classes according to differing in their substrate specificity, behavior in excess substrate and susceptibility to inhibitors: acetylcholinesterase or *true cholinesterase* (AChE) and butyrylcholinesterase (BChE). BChE is also known as non-specific cholinesterase or simply cholinesterase. The aim of this study was to compare the effects of bendiocarbamate on histochemical localization of acetylcholine- and butyrylcholine-positive nerves in rabbit's thymuses.

### Materials and Methods

The study was carried out on 50 European rabbits (*Oryctolagus cuniculus*), hybrid Hyla, of both sexes. The rabbits were 54 days-old with mean BW of 1250 g. The experimental animals were kept under standard conditions in animal quarters at 15-18°C and natural light regimen. They were fed granulated mixed feed and were supplied drinking water *ad libitum*.

The rabbits were placed into large litter less cages, 6 animals in each. The experimental animals were administered bendiocarbamate (96% Bendiokarb tech., Bayer, Leverkusen,

Germany) in the form of capsules *per os* at a dose of 5 mg/kg BW daily for 13 days. Since the animals showed a strong response to the daily administered dose (diarrhoea, dehydration and alopecia in some animals), after 13 days the exposure was decreased by administering the same dose in 48 h intervals. During the experiment, control animals were fed standard granulated mixed feed intended for rabbits. On days 3, 10, 20, 30, 60 and 90 of the experiment, groups of experimental animals consisting of 6 rabbits were euthanized by ether together with control group (8 rabbits) of animals. The experiment was conducted in compliance with the rules set by the Ethical commission of University of Veterinary Medicine in Kosice, Slovakia and conditions for experiments on animals. Samples taken from the thymus were processed for demonstration of AChE-positive and BuChE-positive nerve fibers. During two hours the samples were fixed in 4% formaldehyde at 4°C. Sections were prepared on freezing microtome thick 20 µm and incubated in the incubation solution during the period of 2-4 h at 37°C. The incubation medium (according to method of Karnovsky and Roots<sup>18</sup> and of El Badawi and Schenk<sup>19</sup>) contained acetylthiocholine iodide needed for the visualization of specific AChE, tetraisopropylpyrophosphoramide (iso-OMPA) for inhibition of non-specific AChE was used. In this method acetylcholinesterase present in the cholinergic nerves releases thiocholine from acetylthiocholine which reduces potassium ferricyanide to potassium ferrocyanide, capable of producing insoluble copper ferrocyanide with copper ions (Hatchett's brown).

The method for visualization of butyrylcholinesterase is the same, but the incubation medium contained butyrylthiocholine iodide as an inhibitor of specific AChE instead of acetylthiocholine iodide. The exact composition of incubation solution can be found in Table 1, the final pH of solution was 5.6 to 6.0.

**Table 1. The exact composition of incubation solution for the visualization of specific AChE, according to El Badawi and Schenk.<sup>19</sup> For visualization of BuChE the medium contains butyrylthiocholine iodide as an inhibitor of specific AChE instead of acetylthiocholine iodide.**

Acetylthiocholine iodide	12.5 mg
Distilled water	2.0 mL
0.82% Sodium acetate	15.8 mL
0.6% Acetic acid	0.5 mL
2.94% Sodium citrate	1.2 mL
0.75% Copper sulphate	2.5 mL
0.137% Tetraisopropylpyrophosphoramide	0.5 mL
0.175% Potassium ferrocyanide	2.5 mL

Elaborated samples were assembled on slides and were examined under a light microscope JENALUNAR 2 (Zeiss, Jena, Germany). We assessed visually the density of the nerve fibers in thymuses of both experimental and control rats. The histological preparations were evaluated qualitatively under an optical microscope (Olympus Provis AX). We compare the histochemical localization of acetylcholine- and butyrylcholine-positive nerves in rabbit's thymuses after administration of bendiocarbamate.

## Results

### Nerve fibers of thymus

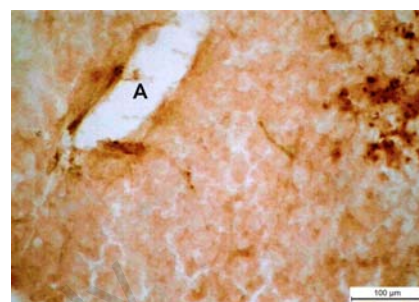
Rabbit thymus of control animals contained AChE- and BuChE-positive nerve fibers in two forms: i) nerve fibers joining to vessels. They formed networks around branches of vessels running in septa and, as a common bundle, headed to organ parenchyma. They entered the cortex layer of the thymus from subcapsular nerve network. The part of the cortex housing numerous lymphocytes was very poor in nerve fibers, while abundant nerve clusters could be observed at the level of cortico-medullary junction, i.e. the part which was a primary starting point of cells and early precursors; ii) nerve fibers independent on vessels. They were most abundant at the cortico-medullary junction and a little less frequent in the medulla.

### Nerve fibers after administration of bendiocarbamate

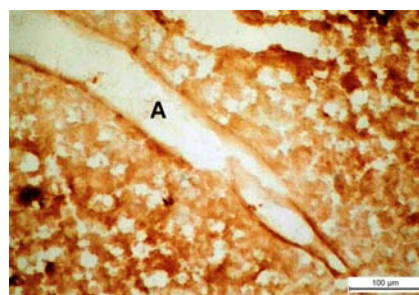
Microscopic findings of BuChE - positive nerve fibers show the same density and the topography by the experimental and the control animals. On the other hand, AChE - positive nerve fibers in experimental animals after administration of bendiocarbamate is poorly identified, suggesting that bendiocarbamate inhibit AChE but not BuChE. Microscopical findings related to AChE-positive innervations of the thymus of rabbits which were administered bendiocarbamate, the inhibitor of AChE, were rather indistinctive (Figures 1 and 2). One could not identify nerve structures with certainty and AChE-positivity was exhibited only by non-neural cellular elements in all experimental materials examined (Figure 3). In the control animals the AChE-positive nerve fibers were observed in the organ capsule in cortex layer originating from the interlobular septum. Fine nerve fibers terminated in the cortex and frequently came to close contact with lymphocytes while in the deep cortex layer and medulla they were

located close to epithelial cells.

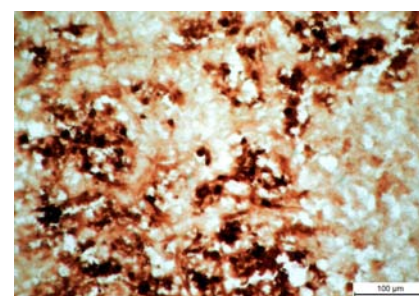
The distributions of BuChE-positive nerve fibers after visualization were the same in experimental and control animals. Nerve fibers entered the thymus as a common bundle with



**Figure 1. Third day of the experiment; nerve fibers are not visualized after administration of bendiocarbamate. A, artery. Scale bar: 100 µm.**

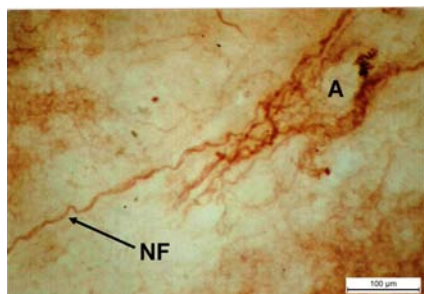


**Figure 2. Day 20 of the experiment. Thymus of an experimental rabbit with very poorly visible AChE-positive fibers in perivascular topography. A, artery. Scale bar: 100 µm.**

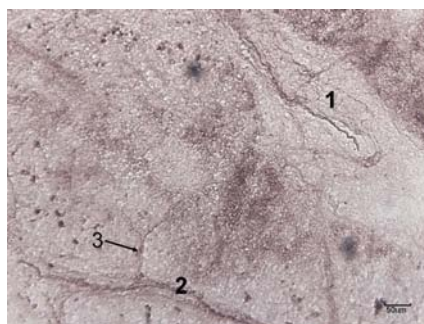


**Figure 3. Day 90 of the experiment. Abundant reaction product in the non-cellular part of thymus of experimental animal lacking AChE-positive nerve fibers. Scale bar: 100 µm.**

arteries, as typical periarterial plexuses (Figure 4). In the organ they were running in interlobular septa as a common bundle of branching off fibers. The highest density of thicker periarterial nerve plexuses with abundance of reaction product was observed at the cortico-medullary junction (Figure 5), while the finer fibers were less abundant in this area. A characteristic feature in this topography was the presence of non-neural cellular elements with high content of colored reaction product. The outer medullary layer contained numerous thicker and thinner nerve fibers. In the cortex layer we observed predominance of fine nerve profiles without evident direct connection to vessels. In the deep cortex topography we were able to observe thicker nerve fibers, particularly close to the cortico-medullary border. Fine BuChE nerve fibers were observed also in the thymic capsule. Based on our findings we can state that BuChE - positive innervations of thymus in experimental and control animals show no differences, it follows bendiocarbamate in dose of 5 mg/kg BW daily not inhibit butyrylcholinesterase.



**Figure 4.** Day 20 of the experiment. Abundant BuChE-positive nerve fibres (NF) in perivascular topography and solitary nerve fibres originating from them. The distribution and the density of nerve fibres are similar to the control animals. A, artery. Scale bar: 100 µm.



**Figure 5.** Third day of the experiment. Fine BuChE-positive nerve fibers (NF) at the cortico-medullary junction. The distribution and the density of nerve fibers are similar to the control animals. Scale bar: 100 µm. A, artery. Scale bar: 100 µm.

## Discussion

The thymus played a key role in the evolution of animals during development of an adaptive immune system; it is therefore an important element, distinguishing higher vertebrates from other animals.<sup>20,21</sup> Our observations of AChE and BuChE-positive nerve fibers in rabbit's thymuses proved their presence in interlobular septa, capsule, cortex, cortico-medullary junction and in the medulla. Our results are in agreement with the observations of authors who investigated autonomic innervations of thymuses in rats and mice.<sup>22-24</sup> Functional changes after administration of cholinesterase inhibitors are characteristic of disorders of metabolic processes responsible for regulation of acid-base balance. Accumulation of acetylcholine results in depolarization of biologic membranes and hypokalaemia.<sup>25</sup> It is well known that surface membranes of various subpopulations of lymphoid cells harbor a number of specific receptors of both conventional neurotransmitters and some peptides. According to Mignini *et al.*,<sup>26</sup> released neurotransmitters may affect functions of T and B lymphocytes as well as the process of entrapping antigens by cells. Our observations that bendiocarbamate blocks specific cholinesterases but will not accumulate in the body of mammals, as after 24 h it is released from mammal tissues either by urine or by lungs or faeces, are in agreement with the results of Ratner *et al.*<sup>25</sup>

Long-term administration of bendiocarbamate caused a decrease in relative proportion of medulla at the expense of cortex which contained hyperplastic reticular cells. Our results allowed us to state that BuChE-positive innervations of thymus did not differ significantly between experimental and control animals, i.e. bendiocarbamate administered at a dose of 5 mg. kg<sup>-1</sup> BW failed to inhibit visualization of BuChE-positive nerve structures. On the other hand, AChE-positive nerve profiles were not visualized in experimental animals after administration of this substance. Bendiocarbamate can affect not only the thymic innervations, but also the dividing of lymphocytes. Holecková *et al.*<sup>27</sup> investigated induction of the unstable chromosomal aberrations, sister chromatid exchanged and stable chromosomal aberration after bendiocarbamate administration in cultured peripheral bovine lymphocytes. They found increase of chromatin breaks frequency. Varga *et al.*<sup>28</sup> found significant positive correlation in thymic size and number of lymphocytes in peripheral blood in newborns.

It has been assumed that suppression of the immune system by some pesticides forms the basis for increased number of allergies, hyper-

sensitivity of organisms and susceptibility to tumour growth.<sup>29,30</sup> One of possible mechanisms of these observations is the oxidative stress: the action of xenobiotics is frequently associated with increased level of reactive forms of oxygen.<sup>31-33</sup>

## References

- Lešník F, Novotná A. Agrochemicals in relation to health of animals and humans. *Slov Vet Cas* 2001;26:14-9 [Article in Slovak].
- Repetto R, Baliga SS. Pesticides and immunosuppression: the risk to public health. *Health Policy Plann* 1997;12:97-106.
- Vos JG, Smialowicz R, Van Loveren H. Animal models for Assessment. Pages 19-30 in: Dean JH, Luster MI, Munson AE, Kimber I. (eds) *Immunotoxicology and Immunopharmacology*. 2nd ed. Raven Press Ltd., New York, USA, 1994.
- Bustnes JO, Hanssen SA, Folstad I, Erikstad KE, Hasselquist D, Skaare JU. Immune function and organochlorine pollutants in Arctic breeding glaucous gulls. *Arch Environ Contam Toxicol* 2004;47:530-41.
- Krall WJ, Sramek JJ, Catler NR. Cholinesterase inhibitors: a therapeutic strategy for Alzheimer disease. *Ann Pharmacotherap* 1999;33:441-50.
- Lane RM, Potkin SG, Enz A. Targeting acetylcholinesterase and butyrylcholinesterase in dementia. *Int J Neuropsychopharmacol* 2006;9:101-24.
- Kristoff G, Guerrero NV, de D'Angelo AM, Cochón AC. Inhibition of cholinesterase activity by azinphos-methyl in two freshwater invertebrates: *Biomphalaria glabrata* and *Lumbriculus variegatus*. *Toxicology* 2006;222:185-94.
- Petrovová E, Sedmera D, Lešník F, Luptáková L. Bendiocarb effect on liver and central nervous system in the chick embryo. *J Environ Sci Health Part B* 2009; 44:383-8.
- Petrovová E, Sedmera D, Mišek I, Lešník F, Luptáková L. Bendiocarbamate toxicity in the chick embryo. *Folia Biologica (Praha)* 2009;55:61-5.
- Geenen V, Brilot F. Role of the thymus in the development of tolerance and autoimmunity towards the neuroendocrine system. *Ann N Y Acad Sci* 2003;992:186-95.
- Varga I, Pospisilova V, Jablonska V, Sisovsky V, Galfiova P, Polak S, et al. Thymic Hassall's bodies of children with congenital heart defects. *Bratisl Lek Listy* 2010;111:552-7.

12. Laurent J, Bosco N, Marche PN, Ceredig R. New insight into the proliferation and differentiation of early mouse thymocytes. *Int Immunol* 2004;16:1069-80.
13. Varga I, Uhrinová A, Toth F, Mistinová J. Assessment of the thymic morphometry using ultrasound in full-term newborns. *Surg Radiol Anat* 2011;33:689-95.
14. Park HY, Hertz-Picciotto I, Petrik J, Palkovicova L, Kocan A, Trnovec T. Prenatal PCB exposure and thymus size at birth in neonates in Eastern Slovakia. *Environ Health Perspect* 2008;116:104-9.
15. Varga I, Pospíšilová V, Jablonska-Mestanova V, Galfiova P, Polak S. The thymus: Picture review of human thymus prenatal development. *Bratisl Lek Listy* 2011; 112:368-76.
16. Varga I, Pospíšilová V, Tóth F, Bevizová K, Polák Š. Factors affecting child thymus size and involution. *Čes-Slov Pediat* 2008;63:209-14 [Article in Slovak].
17. Varga I, Tóth F, Uhrinová A, Neščáková E, Pospíšilová V, Polák Š. Anthropometry, nutrition status and thymic size of Gypsy newborns from Southwestern Slovakia. *Bratisl Lek Listy* 2009;110:354-7.
18. Karnovsky MJ, Roots L. A "Direct-coloring" thiocholine method for cholinesterase. *J Histochem Cytochem* 1964;12:219-21.
19. El Badawi A, Schenk EA. Histochemical methods for separate, consecutive and simultaneous demonstration of acetylcholinesterase and norepinephrine in cryostat section. *J Histochem* 1967;15: 580-8.
20. Varga I, Pospíšilová V, Gmitterová K, Gálfiová P, Polák Š, Galbavý Š. The phylogenesis and ontogenesis of the human pharyngeal region focused on the thymus, parathyroid, and thyroid glands. *Neuroendocrinol Lett* 2008;29:837-45.
21. Bowden TJ, Cook P, Rombout JH. Development and function of the thymus in teleosts. *Fish Shelfish Immunol* 2005; 19:413-27.
22. Nieto-Cerón S, del Campo LF, Delgado EM, Vidal CJ, Campoy FJ. Thymus acetylcholinesterase activity is reduced in mice with congenital muscular dystrophy. *J Mol Neurosci* 2006;30:49-50.
23. Dorko F, Gomboš A, Kočíšová M. Development of the AChE - positive innervation of the rat thymus during prenatal and postnatal period. *Funct Develop Morphol* 1994;4:139-40.
24. Dorko F, Gregor A. A comparative histochemical study of the distribution and density of acetylcholinesterase (AChE) - positive nerves in the thymi of old rats after orchid and ovariectomy. *Folia Veter* 1996;40:39-41.
25. Ratner D, Oren B, Vigder K. Chronic dietary anticholinesterase poisoning. *Israel J Med Sc* 1983;19:810-15.
26. Mignini F, Streccioni V, Amenta F. Autonomic innervation of immune organs and neuroimmune modulation. *Autonom Autacoid Pharmac* 2003;23:1-25.
27. Holecková B, Siviková K, Dianovská J. Effect of N-methylcarbamate pesticide bendiocarb on cattle lymphocytes after in vitro exposure. *Acta Biol Hung* 2009;60:167-75.
28. Varga I, Tóth F, Uhrinová A, Neščáková E, Polák Š. Association among size of thymus, anthropometric dimensions and number of lymphocytes in peripheral blood in newborns from Slovakia. *Biomed Pap Med Fac Univ Palacky Olomouc Czech Repub* 2009;153:229-34.
29. Gleichmann E, Kimber I, Purchase IF. Immunotoxicology: suppressive and stimulatory effects of drugs and environmental chemicals on the immune system. A discussion. *Arch Toxicol* 1989;63:257-73.
30. Mojžišová J, Šulla I. Vplyv pesticídov na imunitný systém zvierat [Influence of pesticides on immune system of animals]. Pages 67-75 in: Danko J, Lešník F, Jenča A (eds). *Xenobiotiká vo vzahu k zdraviu* [Xenobiotics in relationship to health]. University of Veterinary Medicine, Košice, Slovakia, 2005.
31. Parthasarathy NJ, Kumar RS, Manikandan S, Devi RS. Methanol-induced oxidative stress in rat lymphoid organs. *J Occup Health* 2006;48:20-7.
32. Agrawal D, Sultana P, Gupta GSD. Oxidative damage and changes in the glutathione redox system in erythrocytes from rats treated with hexachlorocyclohexane. *Food Chem Toxic* 1991;29:459-62.
33. Holovská K, Lenártová V, Pedrajas JR, Peinado J, López-Barea J, Rosival I, Legáth J. Superoxide dismutase, glutathione peroxidase and glutathione reductase in sheep organs. *Comp Biochem Phys B* 1996; 115:451-56.