

## ORIGINAL PAPER

Eur. J. Histochem.  
46: 249-258, 2002  
© Luigi Ponzio e figlio - Editori in Pavia

### Expression of collagen type I, II, X and Ki-67 in osteochondroma compared to human growth plate cartilage

K. Huch<sup>1</sup>, V. Mordstein<sup>2</sup>, J. Stöve<sup>1</sup>, A.G. Nerlich<sup>3</sup>, H. Arnholdt<sup>4</sup>, G. Dellling<sup>5</sup>, W. Puhl<sup>1</sup>, K.P. Günther<sup>1</sup>, and R.E. Brenner<sup>2</sup>

<sup>1</sup>Department of Orthopaedic Surgery and <sup>2</sup>Division for Biochemistry of Joint and Connective Tissue Diseases University of Ulm, Oberer Eselsberg 45, 89081 Ulm, Germany; <sup>3</sup>Department of Pathology, University of Munich, Thalkirchner Str. 36, 80337 München, Germany; <sup>4</sup>Department of Pathology, Central Hospital, Stenglinstr. 2, 86156 Augsburg, Germany and <sup>5</sup>Department of Osteopathology, University of Hamburg, Martinstraße 52, 20246 Hamburg, Germany

Accepted: 7/05/02

Key words: osteochondroma, multiple exostoses, collagen, Ki-67, immunohistochemistry

#### SUMMARY

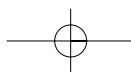
In order to characterize the consequences for the process of endochondral ossification we performed an immunohistochemical study and compared the expression of collagen type I, II and X as markers of cartilage differentiation and Ki-67 as a marker of cell proliferation in solitary (7-26 years, n=9) and multiple (11-42 years, n=6) osteochondromas with their expression in human fetal and postnatal growth plates. In fetal and young postnatal controls, we found a thin superficial layer of articular cartilage that stained positive for collagen type I while collagen II was expressed in the rest of the cartilage and collagen type X was restricted to the hypertrophic zone. Osteochondromas from children showed lobular collagen type II-positive areas surrounded by collagen type I. In adults, the separation of collagen type I- and type II-positive areas was more blurred, or the cartilaginous cap was missing. Collagen type X was detected in a pericellular distribution pattern within hypertrophic zones but also deeper between bone trabecula. The proliferative activity of osteochondromas from children younger than 14 years of age was comparable to postnatal growth plates, whereas in cartilage from individuals older than 14 years of age, we could not detect significant proliferative activity.

#### INTRODUCTION

Osteochondromas (osteocartilaginous exostoses) represent about 50% of benign bone neoplasms (Dahlin 1978, Mirra 1980, Huvos 1991). They occur in bones growing via endochondral ossification, and the tumor itself is believed to be created by the same process. Characteristic features are the close relationship to the growth plate and the continuous bone marrow between the osteochondroma and the original bone. Osteochondromas can be divided into a more frequent solitary sporadic and a multiple hereditary form, both revealing a similar radiological appearance.

Aigner *et al.* (1997) observed a zonal distribution of collagen type X that was characteristically expressed

Correspondence to: K. Huch  
E-mail: klaus.huch@medizin.uni-ulm.de



in hypertrophic cartilage in seven benign osteochondromas. However, information about age, gender and type of the examined osteochondromata is missing in this study as well as information about differences in the immunohistochemical findings in regular growth plates. In the same study, enchondromas and osteosarcomas were characterized by a random distribution of collagen type X expression.

In order to get more detailed information on the pattern of chondrocyte differentiation, we performed an immunohistochemical study and correlated the morphology of solitary and multiple osteochondromas from skeletal immature and mature patients to their expression of collagen type I (found in bone, ligament, etc.), type II (expressed in cartilage), and type X (hypertrophic cartilage), and to the expression of the proliferation marker Ki-67. We also compared their distribution to that observed in human growth plate cartilage from fetal and postnatal joints.

## MATERIALS AND METHODS

### Tissue Sampling

Tissue was obtained from 14 patients undergoing surgery for symptomatic osteochondroma. Histological examination by an osteopathologist (G.D.) confirmed the benign character of all specimens. Complete fingers from 6 babies with hexadactyly were obtained after resection. All samples were fixed in 10% formalin and processed for microscopic examination with or without decalcification. Normal growth plate cartilage from fetal knees (derived from abortuses) and postnatal femoral heads were procured from patients who died from diseases unrelated to the skeleton at autopsy. Details are given in Table I.

### Tissue Processing

All specimens were fixed in 4% buffered formaldehyde for at least 72 hours. After rinsing with tap water, they were decalcified in 10% EDTA solution at pH 7.4 for up to 6 weeks. 2.5  $\mu$ m sections were cut from paraffin-embedded tissue and placed on glass slides pretreated with silane. Hematoxylin-eosin (HE) and safranin-O staining were routinely performed.

### Immunohistochemistry

Deparaffinized samples were incubated with varying enzymes to improve immunoreactivity according to antibody-specific regimens (see Table 2), rinsed in phosphate buffered saline and incubated with the primary antibody overnight at 4°C. Using the streptavidin-biotin method, binding of the secondary antibody to the primary was visualized by 3-amino-9-ethylcarbazol (ACE) as chromogen (LSAB kit, Dako, Hamburg, Deutschland). As a negative control, sections were processed for each sample in the absence of the suitable primary antibody.

The manufacturer (see Table II) of the collagen type I antibody confirmed a cross reactivity with collagen type II, III, IV, V, and VI of less than 10%. According to the same company the cross reactivity of the collagen type II antibody against collagen type I, III, IV, V, and VI is also less than 10%. The specificity of the collagen type X antibody used in this study was well characterized by Girkontaitė *et al.* (1996).

### Data Analysis

For evaluation of collagen type I, II, and X immunohistochemistry, we described patterns of their distribution.

For analysis of Ki-67, negatively- and positively-stained nuclei were counted. The relation between

Table I  
Attributes of human specimens used in this study

Specimens	Number of patients	Age range (average $\pm$ standard deviation)	Source (location)
Solitary exostoses	9	7-26 years (14.2 $\pm$ 6.3)	Surgery
Multiple exostoses	6	11-42 years (19.8 $\pm$ 12.6)	Surgery
Fetal growth plate	7	16-23 gestation week (20.3 $\pm$ 2.4)	Pathology (Augsburg)
Postnatal femoral heads	3	1.5-8 years ( 4.0 $\pm$ 3.5)	Pathology (Munich)
Hexadactyly	6	8 days - 14 months (6.3 $\pm$ 4.1 months)	Surgery

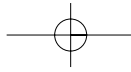


Table II  
Pretreatment protocols used in the study

Antibody against (type, company)	Enzymes for digestion
Collagen type I (polyclonal, Biozol, Southern Biotechnologies Associates, Inc.)	5 mg/ml pronase in Tris-buffered saline (TBS) at pH 7.2
Collagen type II (polyclonal, Biozol, Southern Biotechnologies Associates, Inc.)	2 mg/ml hyaluronidase in phosphate-buffered citric acid at pH 5.0 at 37°C for 30 minutes, followed by 0.5 mg/ml proteinase K in Tris buffer at pH 7.5 at 21°C for 30 minutes
Collagen type X (clon X53, Quartett)	0.5 mg/ml proteinase K in Tris buffer at pH 7.5 at 21°C for 35 minutes, followed by 0.1 mg/ml pepsin in 0.5 M acetic acid at 37°C for 60 minutes
Ki-67 (monoclonal, Dako)	0.01M citrate-buffered citric acid (pH 6.0) and heated in a water bath at 98°C for 35 minutes

positive and total cell numbers was called the "index of proliferative activity" (Stenzel *et al.*, 1996). As recommended by Scotlandi *et al.* (1995), we counted at least 500 cells to calculate the index.

## RESULTS

### Collagen type I

Superficial layers of fetal articular cartilage revealed a small zone with positive staining for collagen type I (Fig. 1B). Two of three postnatal proximal femoral head samples (see table I) revealed a tiny zone with positive staining for collagen type I in their superficial cartilage layers (Fig. 1A). In four of six specimens from resected hexadactylic fingers, superficial cartilage layers were positive for collagen type I as well.

13 of the 15 osteochondromas revealed positive staining for collagen type I in the cartilaginous cap. The cartilage from a solitary exostosis of a 15-year-old girl showed staining, whereas the sample of a 28-year-old woman did not contain a cartilaginous cap. In 12 of the 13 positively stained caps, we found soft tissue formations intersecting the cartilage into lobes, which were positive for collagen type I (Fig. 2A).

### Collagen type II

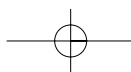
The fetal and postnatal articular cartilage revealed a rather homogenous staining for collagen type II,

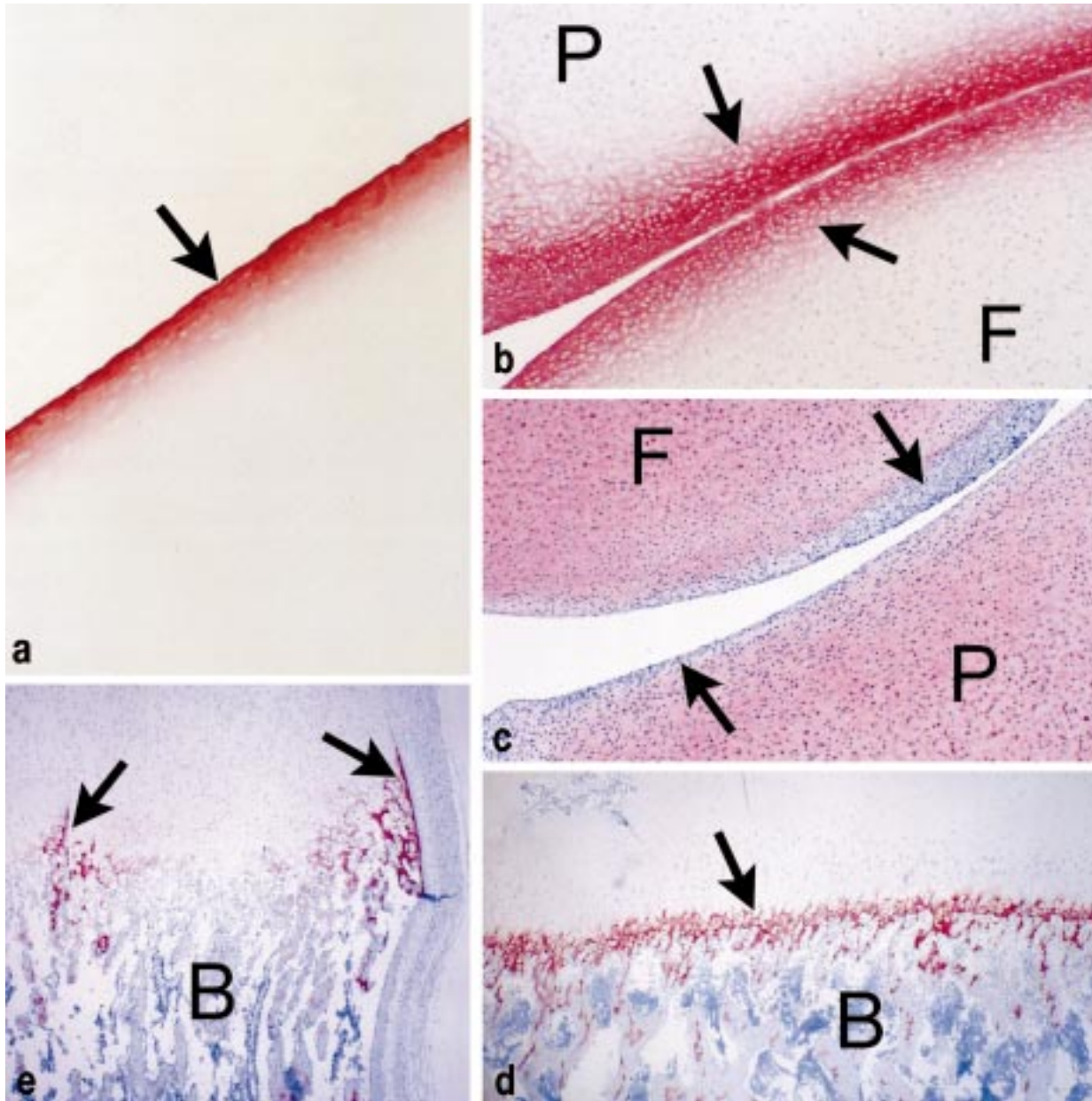
with exception of the thin superficial layer that was positive for collagen type I. The distal bony end of 3 of the 4 fingers (hexadactyly), studied by immunohistochemistry, also showed positive staining for collagen type II (Fig. 3A). Two of these three fingers were examined for collagen type X (Fig. 3B). A positive staining for type X collagen was seen pericellularly, but the surrounding area was collagen type II positive (Fig. 3A).

The distribution of collagen type II in sections of osteochondroma was similar to the negative print of collagen type I staining (Fig. 2B). Collagen type II was also detected in the form of little islands entrapped in newly-formed bone trabecula (Fig. 2B). A similar observation was made for collagen type II staining in articular cartilage, where type II positive areas were type I negative and vice versa (Fig. 1B/C). However, the cartilage of an osteochondroma of a 42-year-old female did not reveal this organized pattern, but a mixed picture of collagen type I and II staining in a more parallel manner resembling fibrous cartilage. The sample of a solitary osteochondroma of a 26-year-old female did not show continuous fibrous intersections. It was only characterized by small fibrous structures next to the bony borderline.

### Collagen type X

Collagen type X was characteristically distributed in the hypertrophic zone of the growth plate

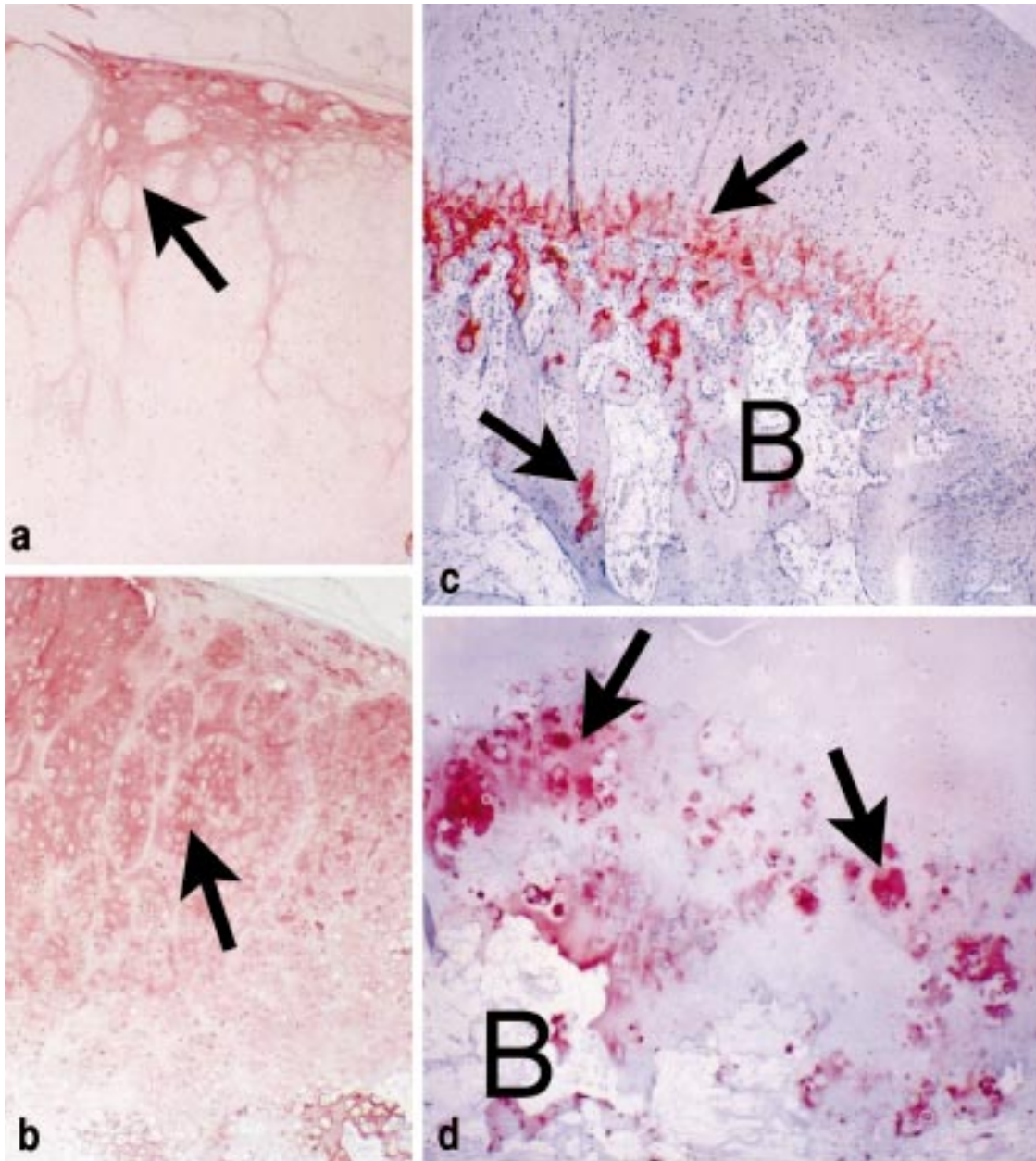




**Fig. 1** - Immunolocalization of collagen type I, II, and X in fetal and postnatal growth plates (B: bone): A) Femoral head of an 8-year-old: Positive immunoreactivity for collagen type I of the surface layer and of the bone (arrow, magnification 125-fold); B) Articulation of femur (F) and patella (P) in a fetal joint (23<sup>rd</sup> week): Positive immunostaining for collagen type I close to the surface (arrows, magnification 125-fold); C) Fetal knee joint (20<sup>th</sup> week): The articular surfaces of the patella (P) and femur (F) contain areas without collagen type II antibody stain (arrows, magnification 100-fold); D) Growth plate of a femoral head (1.5-year-old): Continuous band of collagen type X staining throughout the hypertrophic zone (arrow, magnification 40-fold); E) Growth plate cartilage from a fetal distal femur (23<sup>rd</sup> week): Positive immunoreactivity is demonstrated for collagen type X in the hypertrophic zone (arrows). Enhanced staining was found around blood vessels and close to the perichondrium (magnification 40-fold).

of fetal joints. Areas around blood vessels and close to the perichondrium revealed enhanced staining (Fig. 1D/E). As a postnatal control for col-

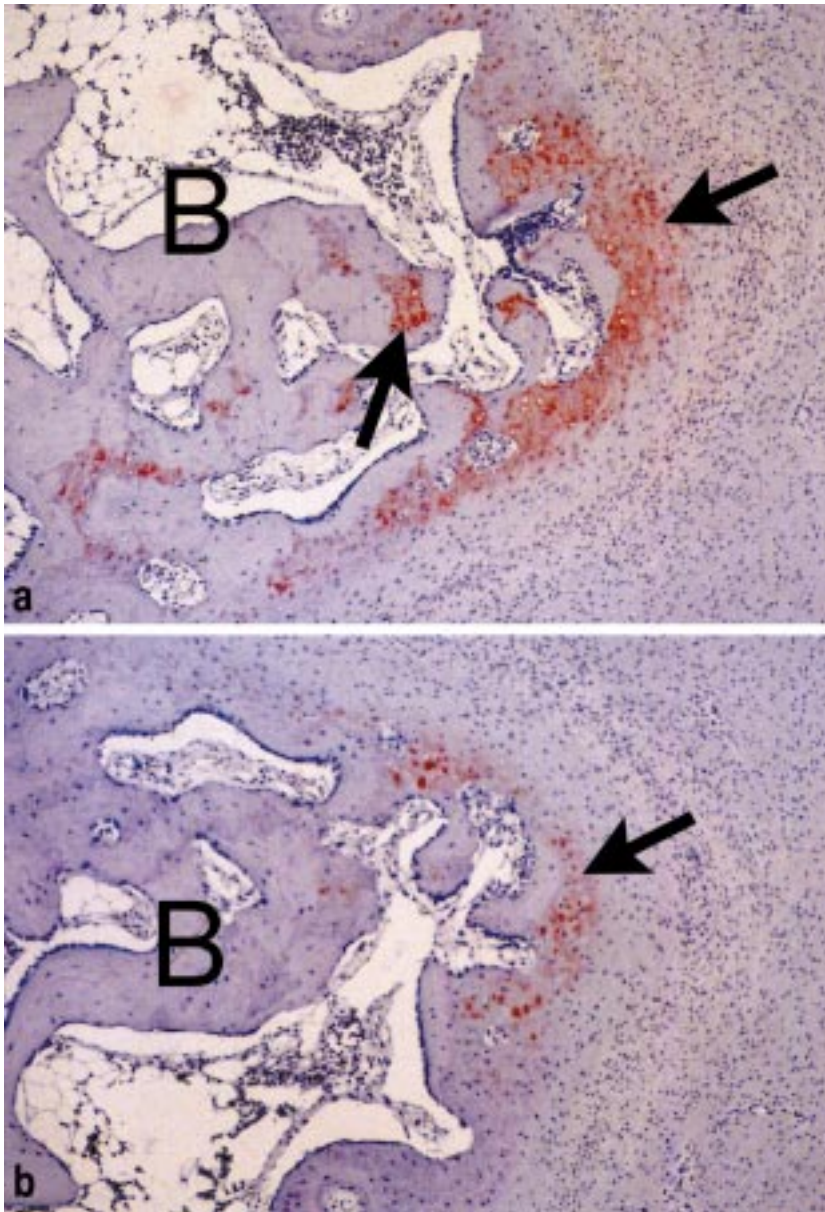
lagen type X staining, we examined the femoral head from a 1.5-year-old boy and found a signal over the total width of the growth plate (Fig. 1D).



**Fig. 2** - Immunolocalization of Osteochondromas (B: bone): A) Osteochondroma of an 11-year-old with multiple exostoses: Collagen Type I antibody stain (arrow) is found in soft tissue bands leading to unstained lobes of cartilage (magnification 125-fold); B) Collagen Type II antibody stain (arrow) is demonstrated complementary to fig. 1A in the cartilaginous cup of the osteochondroma (magnification 125-fold); C) Solitary osteochondroma (7-year old): Collagen type X as a band (arrow) in the hypertrophic zone and in deep cartilage "islands" between bony trabeculae (magnification 50-fold); D) 42-year-old with multiple osteochondromas: Strong, but inconsistent collagen type X immunostaining predominantly pericellular (arrows, magnification 50-fold).

Collagen type X staining varied in hypertrophic cartilage zones from polydactyly. Two neighboring growth zones of a finger joint from a 10-month-old girl differed strongly in their type X expression pattern. One zone was stained like a band, the other

mainly revealed pericellular staining. Consistently, there was an obvious correlation between morphology of the hypertrophic zone and type X staining: the more calcification the less type X. Nine of the 14 exostoses with a cartilaginous cap



**Fig. 3** - Immunolocalization of type II and X collagen in the end phalanx of an additional finger in hexadactyly of a 6-month-old baby (B: bone): A) Collagen type II expression (arrow) is demonstrated subperiosteally at the top of the phalanx (magnification 80-fold); B) Collagen type X antibody stain (arrow) can be seen pericellularly at the top of the phalanx (magnification 80-fold).

had a continuous band of positive type X staining over the width of their growth zone. Collagen type X together with type II was also found relatively deep in cartilage “islands” between bone trabecula (Fig. 2C). One of those nine, (from a 42-year old male with multiple exostoses) did not contain a growth zone, but showed a tidemark with positive type X staining next to it. Four of the 14 samples revealed a predominantly pericellular but inconsistent staining of the growth zone (Fig. 2D). One specimen (from a 26-year-old female with solitary

exostosis) was characterized by a tidemark and infrequent type X positive cells with pericellular staining.

#### **Ki-67**

Immunohistochemistry for Ki-67 allowed us to determine the index of proliferative activity for growth plate (like) cartilages of fetal joints, hexadactyly and osteochondroma. The values for different entities are presented in Table III. The osteochondromas from the five individuals older

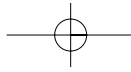


Table III  
Index of proliferative activity for growth plate cartilage in various entities (average  $\pm$  standard deviation in %, \*comparable to Apte *et al.*, 1992)

Osteochondroma		Fetal growth plate	Hexadactyly
< 14-year old	$\geq$ 14-year old		
n = 10	n = 5	n = 7	n = 6
6.2 $\pm$ 8	0	*47.2 $\pm$ 5.0	6.5 $\pm$ 6.7

than 14 years of age did not reveal positive staining for Ki-67, those from younger individuals differed independently of their age and of their type (solitary or multiple). Hypertrophic cartilage did not show staining for Ki-67 as already described by Apte *et al.* (1990).

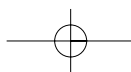
## DISCUSSION

The (positive) staining for collagen type I in young *human* articular cartilage from fetal knee joints, postnatal femoral heads and resected fingers (hexadactyly), was a new finding. Accordingly, immunostaining for collagen type II was less intense or abandoned in superficial layers of articular cartilage. Von der Mark (1981) described collagen type I in the superficial layers from *chicken* articular cartilage and Pfander *et al.* (1999) detected collagen type I in superficial *rabbit* articular cartilage. Allard *et al.* (1990) showed microscopic photographs with synovial lips on *human* articular cartilage close to the cartilage-synovial junction. These lips continued as fibroblastic layers to the middle of the joint. Collagen type I expression was not investigated in this study. Taken together, the observation of collagen type I positive intercellular matrix on the surface of human articular cartilage might be a residue of a perichondral layer.

The organization of growth plates from additional fingers in patients with polydactyly was similar to other fetal or postnatal growth plates. Accordingly, collagen type II and X in the distal end of hexadactylic fingers might be remnants from a growth plate (endochondral ossification). Safranin-O staining could demonstrate proteoglycans in the same area of the distal phalanx (data not shown), which would support our hypothesis.

Hereditary multiple exostoses (HME) are linked to three loci on chromosomes 8q24 (EXT1), 11p11-13 (EXT2), and 19p (EXT3) (Cook *et al.*, 1993, Le Merrer *et al.*, 1994, Wu *et al.*, 1994). EXT1 and EXT2 have been cloned (Ahn *et al.*, 1995, Stickens *et al.*, 2000, Wuyts *et al.*, 1996) and mutations in these genes have been identified in sporadic and hereditary exostoses (Wuyts *et al.*, 1998, Bovée *et al.*, 1999, Wuyts *et al.*, 2000). EXT1 and EXT2 are regarded as tumor suppressor genes (Porter and Simpson 1999), and their corresponding gene products have recently been shown to catalyze the biosynthesis of heparan sulfate proteoglycans (Lind *et al.*, 1998, Mc Cormick *et al.*, 1998). This may influence the diffusion of hedgehog proteins (Bellaiche *et al.*, 1998). Since hedgehog proteins are known to play an important role in the regulation of endochondral ossification, their capacity for diffusion may represent a central factor within the pathogenesis of osteochondromas (Bellaiche *et al.*, 1998).

Osteochondromas from young patients are characterized by lobes of hyaline-appearing-cartilage (collagen type II positive) and fibrous intersections (collagen type I positive). The presence and uneven distribution of collagen type I within an osteochondroma was described previously in one young patient with a mutation of EXT1 (Legeai-Mallet *et al.*, 2000). Age-related changes of osteochondromas embody a possible degeneration including complete disappearance of the cartilaginous cap as discussed by Dahlin (1978) and Mirra (1980). In a 28-year-old female, the second oldest patient in our study, we have not found a cartilaginous cap; however, radiographs ascertained the diagnosis of osteochondroma. A 42-year-old male, the oldest patient included in our study, displayed a more mixed picture of collagen type I and II distribution resembling fibrous cartilage of the nucleus pulposus as described by Nerlich *et al.* (1997),



who demonstrated an age-correlated increase of antibody staining for collagen type I and a decrease for type II. Similar to Aigner *et al.* (1997), we found collagen type II and X in cartilage islands between bone trabecula of osteochondromas. In our series, positive pericellular stain was found relatively deep in the bony area, indicating a more irregular pattern as observed in human fetal growth plates (Girkontaité *et al.*, 1996). A consistently enhanced expression of type X collagen and presence in non-hypertrophic areas as described in one patient by Legeai-Mallet *et al.*, (Legeai-Mallet *et al.*, 2000) was not observed. In our patients, collagen type X staining as well as cartilage intersections did show variations, but do not appear to be type related (solitary versus multiple).

Osteochondroma can be regarded as a neoplastic process, which will develop, if members of the EXT family are inactivated. This leads to a disturbance in the biosynthesis of heparan sulfate glycosaminoglycans since EXT1 and EXT2 are important for normal glycosyltransferase activity (Mc Cormick *et al.*, 2000). Resulting alterations in the expression of cell-surface heparan sulfate proteoglycans (Mc Cormick *et al.*, 1998) which interact with numerous growth/differentiation factors such as bFGF, and diminished diffusion of the signaling protein indian hedgehog (Bellaiche *et al.*, 1998), are thought to be responsible for local abnormalities in chondrocyte differentiation. Such mechanisms could contribute to the observation of intersections of collagen type I between islands of hyaline cartilage, the persistent immunostaining for type II and X collagen relatively deep between bony trabecules and the presence of type X collagen in adult osteochondroma. Due to the lack of hypertrophic chondrocytes, Boos *et al.* (1999) did not find this collagen type in normal adult cartilage. Since Aigner *et al.* (1997) did not characterize their patients for age, it is unknown whether they observed type X in adult osteochondroma.

To our knowledge, we have performed the first analysis of Ki-67 in osteochondroma and postnatal (human) growth plates. For proliferative activity of fetal growth plates, we found comparable values (40-50%) to Apte and Athanasou (1992), indicating a reliable technique for our Ki-67 analysis. Proliferative activity in osteochondroma from children under the age of 14 years ( $11.3 \pm 1.9$  years) was

comparable to values obtained for growth plates from hexadactyly ( $6.3 \pm 4.1$  years) (see Table III). However, like in adult articular cartilage or enchondroma (Davis *et al.*, 1998), Ki-67 could not be detected in post-puberty specimens of osteochondroma ( $26.8 \pm 9.83$  years). This supports the statements of Solomon (1964) and Scarborough (1996) about the end of endochondral ossification in osteochondroma with skeletal maturity. Therefore, Ki-67-positive cells in cartilage of adult osteochondroma may rather suggest malignant transformation, which is clinically suspected in growing osteochondromas or in a cartilage cap thickness above 2 cm.

In conclusion, we could show that osteochondromas from children have lobular collagen type II positive areas surrounded from fibrous, collagen type I positive intersections whereas, in adults, a process of degeneration or involution leads to a change in the organization of the cartilage with a more blurred separation of collagen type I- and II-positive areas or even a disappearance of the cartilaginous cap. Collagen type X is actively expressed and especially found pericellular in hypertrophic zones but also deeper between bony trabecules. Proliferative activity of osteochondromas from children under the age of 14 years is comparable to postnatal growth plates, whereas cartilage from adult osteochondroma reveals no relevant proliferative activity. Therefore, a higher number of Ki-67-positive cells in adult osteochondroma might serve as an additional indicator for malignancy.

## ACKNOWLEDGMENTS

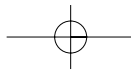
The authors thank Mrs. Brunhilde Amann for her skilled technical assistance.

## REFERENCES

- Ahn J., Ludecke H.J., Lindow S., Horton W.A., Lee B., Wagner M.J., Horsthemke B., and Wells D.E.: Cloning of the putative tumour suppressor gene for hereditary multiple exostoses (EXT1). *Nat. Genet.* 11, 137-143, 1995.
- Aigner T., Frischholz S., Dertinger S., Beier F., Girkontaité I., and von der Mark K.: Type X collagen expression and hypertrophic differentiation in chondrogenic neoplasias. *Histochem Cell Biol.* 107, 435-440, 1997.



- Allard S.A., Bayliss M.T., and Maini R.N.: The synovium-cartilage junction of the normal human knee. Implications for joint destruction and repair. *Arthritis Rheum.* 33, 1170-1179, 1990.
- Apte S.S., and Athanasou N.A.: An immunohistological study of cartilage and synovium in primary synovial chondromatosis. *J. Pathol.* 166, 277-281, 1992.
- Apte S.S.: Expression of the cell proliferation-associated nuclear antigen reactive with the Ki-67 monoclonal antibody by cells of the skeletal system in humans and other species. *Bone Miner.* 10, 37-50, 1990.
- Bellaiche Y., The I., and Perrimon N.: Tout-velu is a Drosophila homologue of the putative tumour suppressor EXT-1 and is needed for Hh diffusion. *Nature* 394(6688), 85-88, 1998.
- Boos N., Nerlich A.G., Wiest I., von der Mark K., Ganz R., and Aebi M.: Immunohistochemical analysis of type X-collagen expression in osteoarthritis of the hip joint. *J. Orthop. Res.* 17, 495-502, 1999.
- Bovée J.V., Cleton-Jansen A.M., Wuyts W., Caethoven G., Taminiou A.H., Bakker E., Van Hul W., Cornelisse C.J., and Hogendoorn P.C.: EXT-mutation analysis and loss of heterozygosity in sporadic and hereditary osteochondromas and secondary chondrosarcomas. *Am. J. Hum. Genet.* 65, 689-698, 1999.
- Cook A., Raskind W., Blanton S.H., Pauli R.M., Gregg R.G., Francomano C.A., Puffenberger E., Conrad E.U., Schmale G., Schellenberg G., Wijsman E., Hecht J.T., Wells D., and Wagner M.J.: Genetic heterogeneity in families with hereditary multiple exostoses. *Am. J. Hum. Genet.* 53, 71-79, 1993.
- Dahlin D.C.: Bone tumors: general aspects and data on 6221 cases. 3<sup>rd</sup> ed, Thomas, Springfield, IL, pp 17-28, 1978.
- Davis R.I., Foster H., Arthur K., Trewin S., Hamilton P.W., and Biggart D.J.: Cell proliferation studies in primary synovial chondromatosis. *J. Pathol.* 184, 18-23 1998.
- Girkontaitė I., Frischholz S., Lammi P., Wagner K., Swoboda B., Aigner T., and von der Mark K.: Immunolocalization of type X collagen in normal fetal and adult osteoarthritic cartilage with monoclonal antibodies. *Matrix Biol.* 15, 231-238, 1996.
- Huvos A.G.: Bone tumors. Diagnosis, treatment, and prognosis. WB Saunders Co., Philadelphia, 253-293, 1991.
- Le Merrer M., Legeai-Mallet L., Jeannin P.M., Horsthemke B., Schinzel A., Plauchu H., Toutain A., Achard F., Munnich A., and Maroteaux P.: A gene for hereditary multiple exostoses maps to chromosome 19p. *Hum Mol Genet* 3, 717-722, 1994.
- Legeai-Mallet L., Rossi A., Benoist-Lassel C., Piazza R., Mallet J.F., Delezoide A.L., Munnich A., Bonaventure J., and Zylberberg L.: EXT 1 gene mutation induces chondrocyte cytoskeletal abnormalities and defective collagen expression in the exostoses. *J. Bone Miner. Res.* 15, 1489-1500, 2000.
- Lind T., Tufaro F., McCormick C., Lindahl U., and Lidholt K.: The putative tumor suppressors EXT1 and EXT2 are glycosyltransferases required for the biosynthesis of heparan sulfate. *J. Biol. Chem.* 273, 26265-26268, 1998.
- McCormick C., Duncan G., Goutsos K.T., and Tufaro F.: The putative tumor suppressors EXT1 and EXT2 form a stable complex that accumulates in the Golgi apparatus and catalyzes the synthesis of heparan sulfate. *Proc. Natl. Acad. Sci. USA* 97, 668-673, 2000.
- McCormick C., Leduc Y., Martindale D., Mattison K., Esford L.E., Dyer A.P., and Tufaro F.: The putative tumour suppressor EXT1 alters the expression of cell-surface heparan sulfate. *Nat. Genet.* 19, 158-161, 1998.
- Mirra J.M.: Bone tumors: diagnosis and treatment. Lippincott JB, Philadelphia, pp 520-532, 1980.
- Nerlich A.G., Schleicher E.D., and Boos N.: 1997 Volvo Award winner in basic science studies. Immunohistologic markers for age-related changes of human lumbar intervertebral discs. *Spine* 22, 2781-1795, 1997.
- Pfander D., Rahmzadeh R., and Scheller E.E.: Presence and distribution of collagen II, collagen I, fibronectin, and tenascin in rabbit normal and osteoarthritic cartilage. *J. Rheumatol.* 26, 386-394, 1999.
- Porter D.E., and Simpson A.H.R.W.: The neoplastic pathogenesis of solitary and multiple osteochondromas. *J. Pathol.* 188, 119-125, 1999.
- Scarborough M.T., and Moreau G.: Benign cartilage tumors. *Ped. Orthop. Oncology* 27, 583-589, 1996.
- Scotlandi K., Serra M., Manara C., Maurici D., Benini S., Nini G., Campanacci M., and Baldini N.: Clinical relevance of Ki-67 expression in bone tumors. *Cancer* 75, 806-814, 1995.
- Solomon L.: Hereditary multiple exostosis. *Am. J. Hum. Genet.* 16, 351-363, 1964.
- Stenzel I., Pösl M., Ritzel H., Hentz M., Werner M., and Delling G.: Zellproliferation bei Knochentumoren. Immunhistologische Untersuchung zur Ki-67-Protein expression. *Pathologie* 17, 56-62, 1996.
- Stickens D., Brown D., and Evans G.A.: EXT genes are differentially expressed in bone and cartilage during mouse embryogenesis. *Dev. Dyn.* 218, 452-64, 2000.
- von der Mark K.: Localization of collagen types in tissues. *Int. Rev. Connect Tissue Res.* 9, 265-324, 1981.
- Wu Y.Q., Heutink P., de Vries B.B., Sandkuijl L.A., van den Ouweland A.M., Niermeijer M.F., Galjaard H., Reyniers E., Willems P.J., and Halley D.J.: Assignment of a second locus for multiple exostoses to the pericentromeric region of chromosome 11. *Hum. Mol. Genet.* 3, 167-171, 1994.
- Wuyts W., Van Hul W., De Boule K., Hendrickx J., Bakker E., Vanhoenacker F., Mollica F., Ludecke H.J., Sayli B.S., Pazzaglia U.E., Mortier G., Hamel B., Conrad E.U., Matsushita M., Raskind W.H., and Willems P.J.: Mutations in the EXT1 and EXT2 genes in hereditary multiple exostoses. *Am. J. Hum. Genet.* 62, 346-354, 1998.
- Wuyts W., Van Hul W., Wauters J., Nemtsova M., Reyniers E., Van Hul E.V., De Boule K., de Vries B.B., Hendrickx J., Herrygers I., Bossuyt P., Balemans W., Fransen E., Vits L.,



Coucke P., Nowak N.J., Shows T.B., Mallet L., van den Ouweland A.M., McGaughran J., Halley D.J., and Willems P.J.: Positional cloning of a gene involved in hereditary multiple exostoses. *Hum. Mol. Genet.* 5, 1547-1557, 1996.

Wuyts W., and Van Hul W.: Molecular basis of multiple exostoses: mutations in the EXT1 and EXT2 genes. *Hum. Mutat.* 15, 220-227, 2000.

