

DOI: [10.4081/ejh.2019.2998](https://doi.org/10.4081/ejh.2019.2998)

Morphological and ultrastructural analysis of normal, injured and osteoarthritic human knee menisci

Michela Battistelli,¹ Marta Favero,² Debora Burini,¹ Giovanni Trisolino,³
Dante Dallari,⁴ Lucia De Franceschi,⁴ Steven R. Goldring,⁵ Mary B. Goldring,⁵
Elisa Belluzzi,^{2,6} Giuseppe Filardo,⁷ Brunella Grigolo,⁸ Elisabetta Falcieri,¹
Eleonora Olivetto⁸

¹Department of Biomolecular Sciences, Urbino University "Carlo Bo", Urbino, Italy

²Rheumatology Unit, Department of Medicine (DIMED), University Hospital of Padua, Italy

³Pediatric Orthopedic and Traumatology, IRCCS Istituto Ortopedico Rizzoli, Bologna, Italy

⁴Reconstructive Orthopedic Surgery Innovative Techniques - Musculoskeletal Tissue Bank; Revision surgery of hip prosthesis and development of new implants, IRCCS Istituto Ortopedico Rizzoli, Bologna, Italy

⁵Hospital for Special Surgery, New York, NY, USA

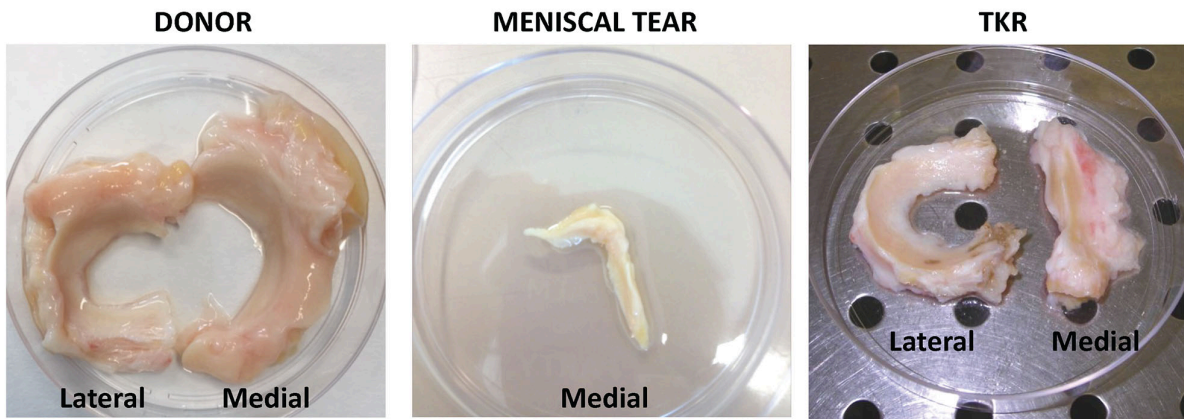
⁶Musculoskeletal pathology and Oncology Laboratory, DISCOG, University of Padua, Italy

⁷ATRC-Laboratory, IRCCS Istituto Ortopedico Rizzoli, Bologna, Italy

⁸RAMSES Laboratory, RIT Department, IRCCS Istituto Ortopedico Rizzoli, Bologna, Italy

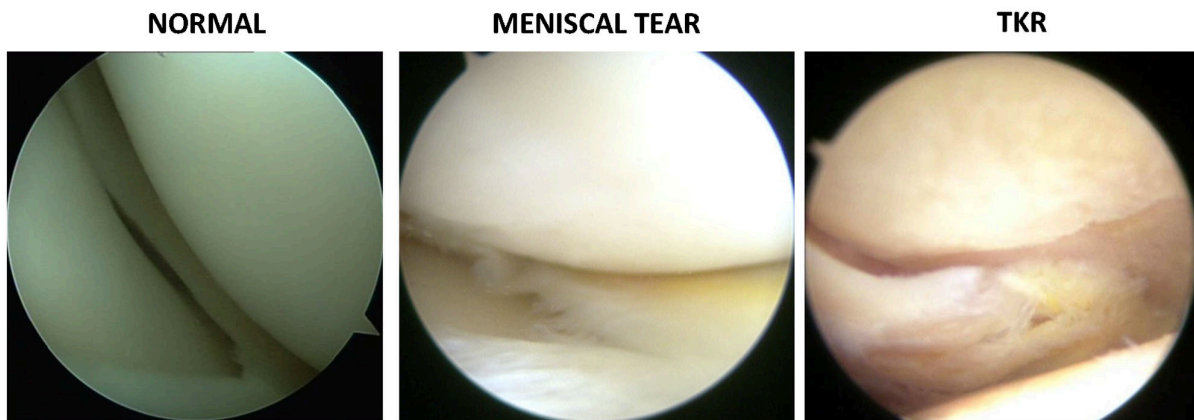Correspondence: Michela Battistelli, University of Urbino "Carlo Bo", Via Ca' le Suore 2, 61029 Urbino (PU), Italy. Tel. +39.0722.304269. E-mail: michela.battistelli@uniurb.it

Key words: Meniscus; meniscal tear; osteoarthritis; transmission electron microscopy; extracellular matrix degeneration.



Supplementary Figure 1.

Macroscopic images of the menisci/meniscal specimens collected during arthroscopic surgery from one normal subject and from two patients with either meniscal tear or end-stage osteoarthritis undergoing total knee replacement (TKR).



Supplementary Figure 2.

Images from arthroscopic videotape collected during diagnostic arthroscopy from patients with or without meniscal tear, and a patient with end-stage osteoarthritis undergoing TKR.