

DOI: [10.4081/ejh.2021.3173](https://doi.org/10.4081/ejh.2021.3173)

Expressions of ZNF436, β -catenin, EGFR, and CMTM5 in breast cancer and their clinical significances

Zhi Chen,¹ Na Cui,² Ji-sen Zhao,¹ Jian-fei Wu,¹ Fang Ma,¹ Cong Li,¹ Xian-yi Liu³

¹ Department of Hepatobiliary Surgery, Affiliated Hospital of Hebei University, Baoding, Hebei

² Department of ICU, Affiliated Hospital of Hebei University, Baoding, Hebei

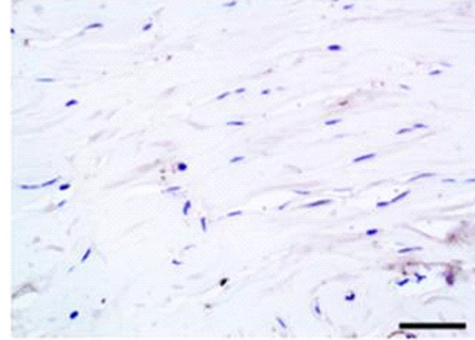
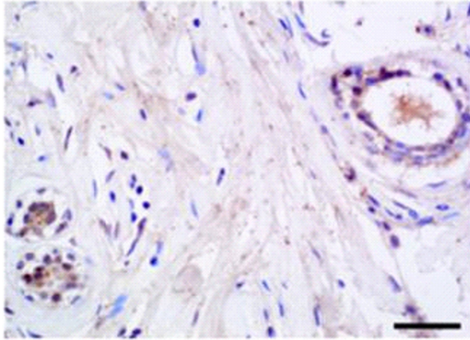
³ Department of Breast Surgery, Affiliated Hospital of Hebei University, Baoding, Hebei, China

Correspondence Xian-yi Liu, Department of Breast Surgery, Affiliated Hospital of Hebei University, Baoding, Hebei 071000, China. E-mail: nzix32@163.com

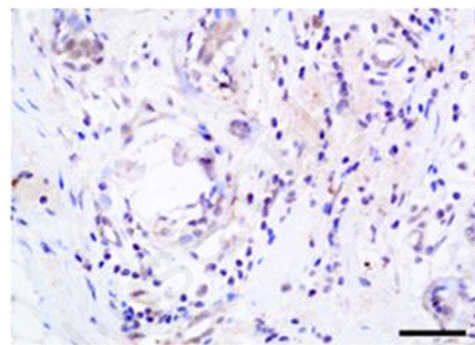
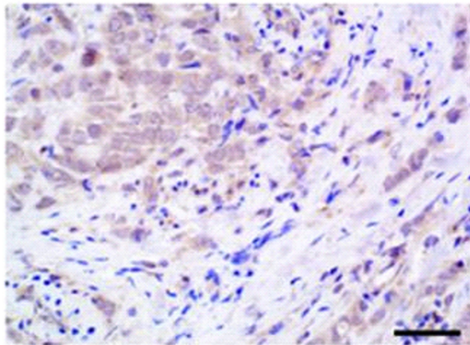
Key words Breast cancer; ZNF436; β -catenin; EGFR; CMTM5; immunohistochemistry.

Cancer tissue

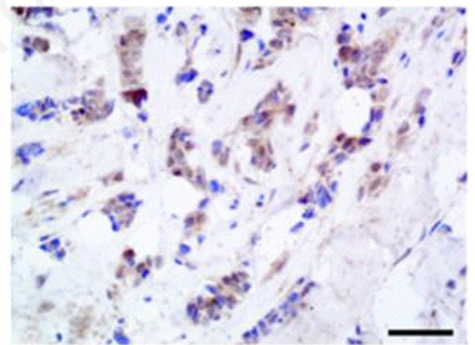
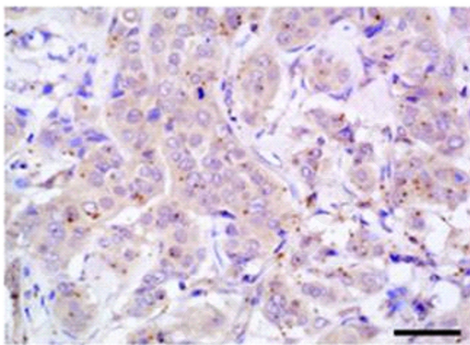
Paracancerous tissue



ZNF436 Poorly differentiated



ZNF436 Moderately differentiated

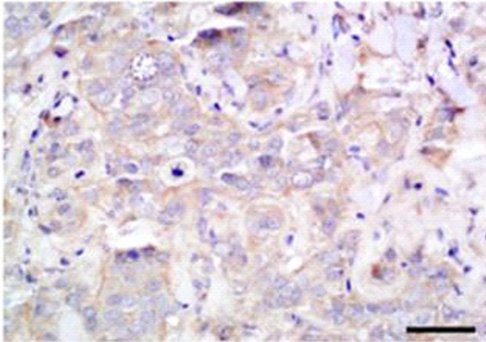


ZNF436 Highly differentiated

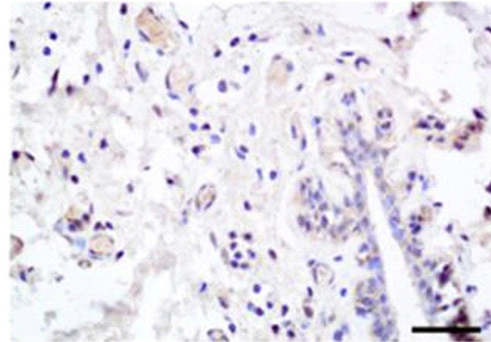
Supplementary Figure 1.

Immunostaining intensity for ZNF436 was higher in breast cancer tissue than in the adjacent paracancerous tissue.

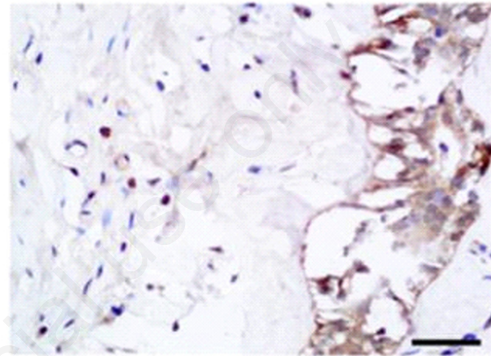
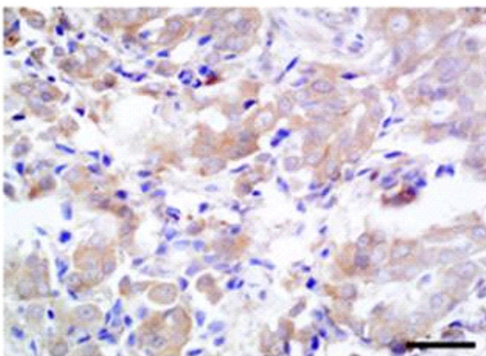
Cancer tissue



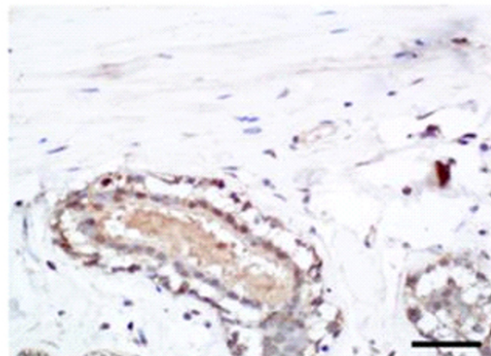
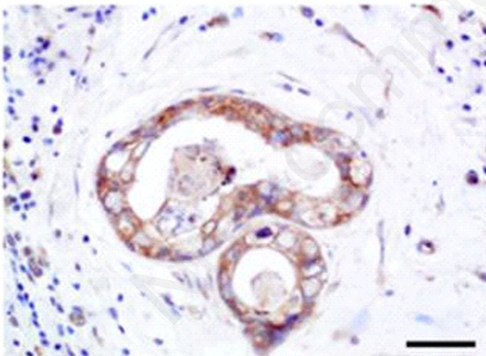
Paracancerous tissue



β -catenin Poorly differentiated



β -catenin Moderately differentiated

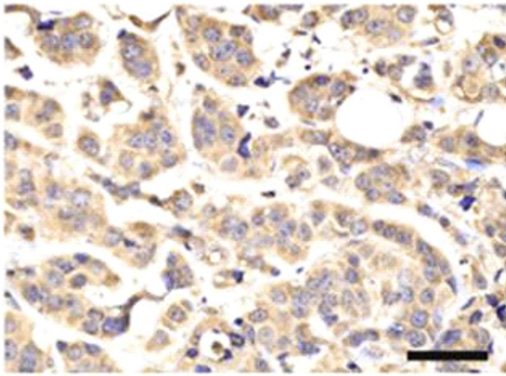


β -catenin Highly differentiated

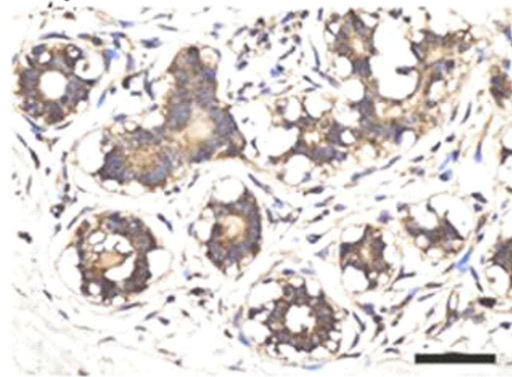
Supplementary Figure 2.

Immunostaining intensity for β -catenin was higher in breast cancer tissue than in the adjacent paracancerous tissue.

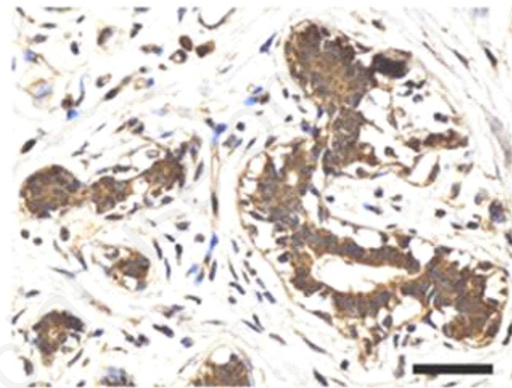
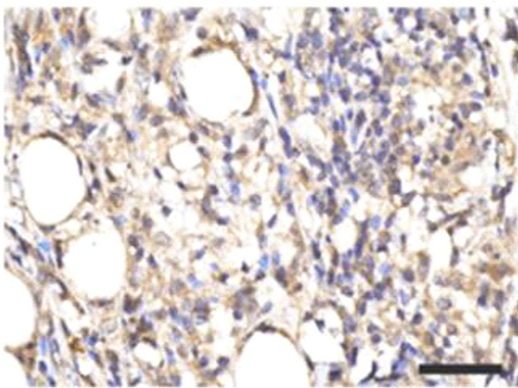
Cancer tissue



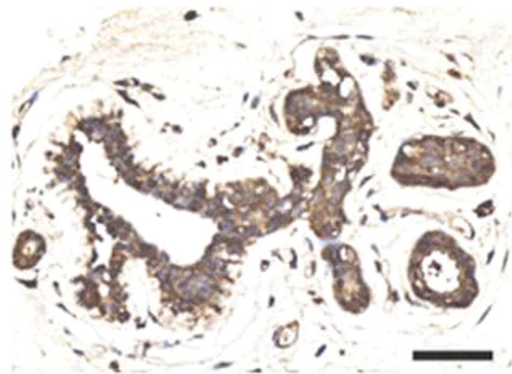
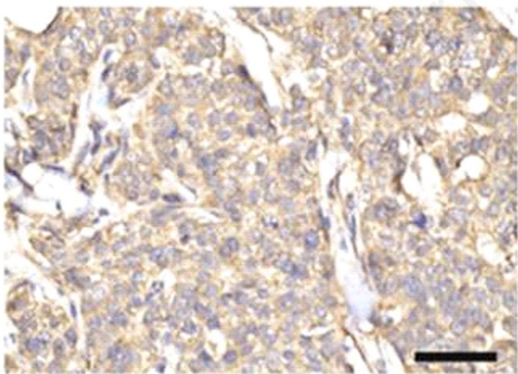
Paracancerous



EGFR Poorly differentiated



EGFR Moderately differentiated



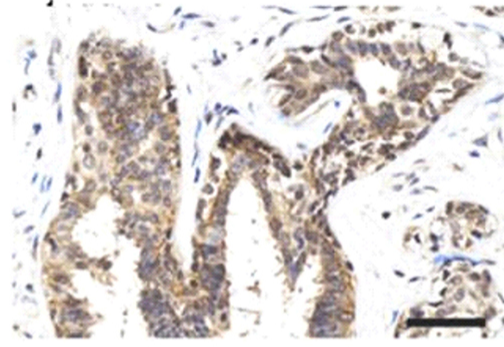
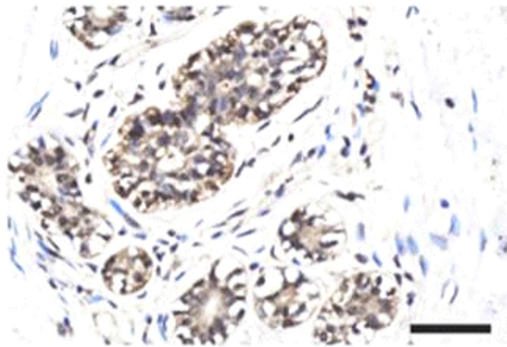
EGFR Highly differentiated

Supplementary Figure 3.

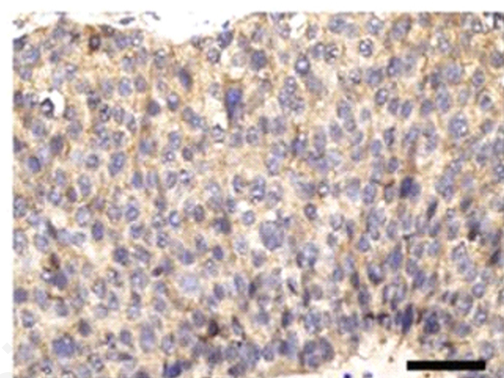
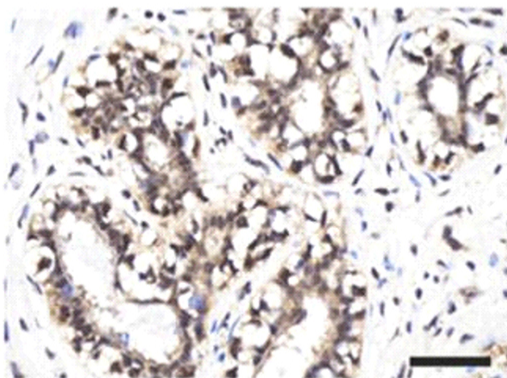
Immunostaining intensity for EGFR was higher in breast cancer tissue than in the adjacent paracancerous tissue.

Cancer tissue

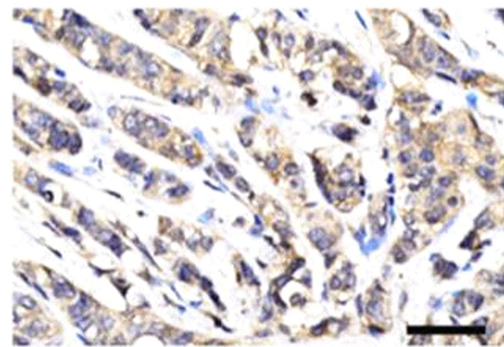
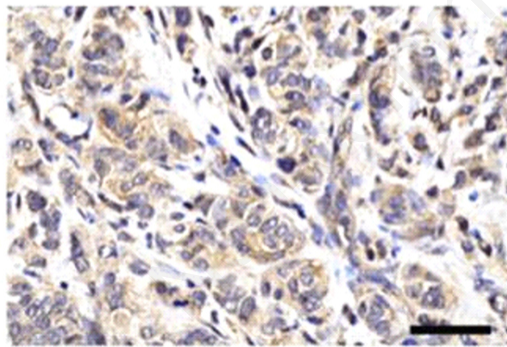
Paracancerous



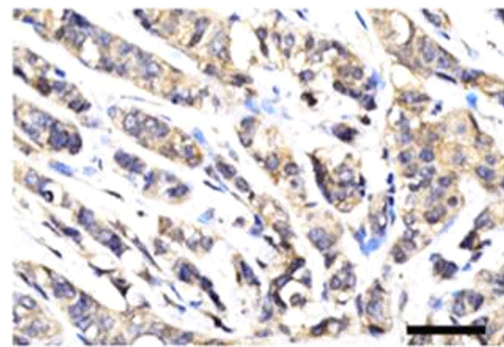
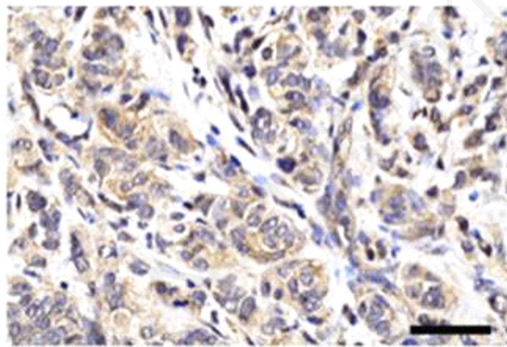
CMTM5 Poorly differentiated



CMTM5 Moderately differentiated



CMTM5 Highly differentiated



Supplementary Figure 4.

Immunostaining intensity for CMTM5 was more highly expressed in the paracancerous tissue than in breast cancer tissue.