



European Journal of Histochemistry

SUPPLEMENTARY MATERIAL

DOI: [10.4081/ejh.2022.3315](https://doi.org/10.4081/ejh.2022.3315)

**Mammaglobin, GATA-binding protein 3 (GATA3), and epithelial growth factor receptor (EGFR) expression in different breast cancer subtypes and their clinical significance**

**Xin Kong,<sup>1,2</sup> Qi Wang,<sup>1,2</sup> Jie Li,<sup>1,2</sup> Ming Li,<sup>1,2</sup> Fusheng Deng,<sup>3</sup> Chuanying Li<sup>1,2,4</sup>**

<sup>1</sup>Department of Pathology, The First Affiliated Hospital of USTC, Division of Life Sciences and Medicine, University of Science and Technology of China, Hefei, Anhui

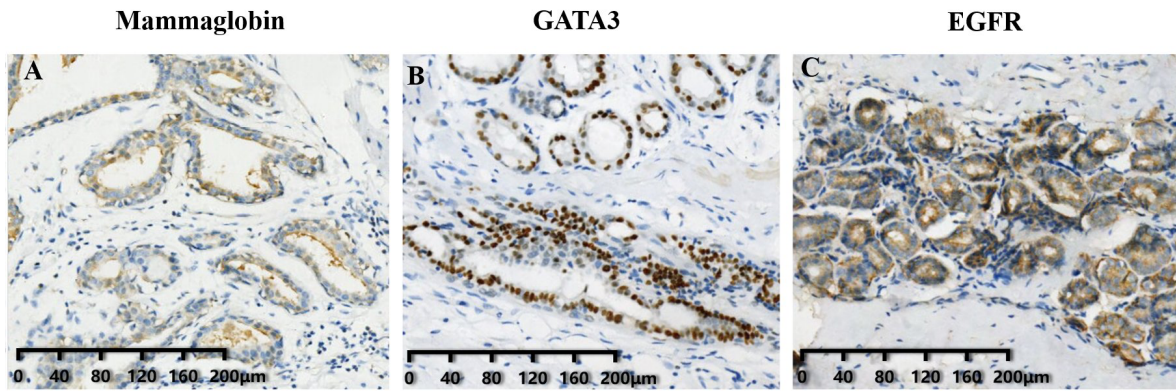
<sup>2</sup>Intelligent Pathology Institute, Division of Life Sciences and Medicine, University of Science and Technology of China, Hefei, Anhui

<sup>3</sup>Department of General Surgery, The First Affiliated Hospital of University of Science and Technology of China, Hefei, Anhui

<sup>4</sup>Department of Pathology, Ruijin Hospital, Shanghai Jiaotong University School of Medicine, Shanghai, China

**Correspondence:** Chuanying Li, MD, Department of Pathology, Ruijin Hospital, Shanghai Jiaotong University School of Medicine, Shanghai 200025, China. Tel. +86.021.64370045. E-mail: lcy12224@rjh.com.cn

**Key words:** breast cancer; mammaglobin; GATA-binding protein 3; epithelial growth factor receptor; molecular subtype.



**Supplementary Figure 1.**

Immunohistochemical analysis of mammaglobin, GATA3, and EGFR expression in normal breast cancer tissues. A: mammaglobin expression in normal lobule of mammary gland. B: GATA3 expression in normal lobule and lactiferous ducts of mammary gland. C: EGFR expression in normal lobule of mammary gland.