

## Is mastocytic colitis a specific clinical-pathological entity?

Filippo Vernia,<sup>1\*</sup> Tiziana Tatti,<sup>2\*</sup> Stefano Necozone,<sup>3</sup> Annalisa Capannolo,<sup>4</sup> Nicola Cesaro,<sup>1</sup> Marco Magistrone,<sup>1</sup> Marco Valvano,<sup>1</sup> Simona Pompili,<sup>5</sup> Roberta Sferra,<sup>5</sup> Antonella Vetusch, <sup>5</sup> Giovanni Latella<sup>1</sup>

<sup>1</sup>Gastroenterology Unit, Department of Life, Health and Environmental Sciences, University of L'Aquila

<sup>2</sup>Pathology Unit, S. Salvatore Academic Hospital, L'Aquila

<sup>3</sup>Epidemiology Unit, Department of Life, Health and Environmental Sciences, University of L'Aquila

<sup>4</sup>Diagnostic and Surgical Endoscopy Unit, San Salvatore Academic Hospital, L'Aquila

<sup>5</sup>Department of Biotechnological and Applied Clinical Sciences, University of L'Aquila, Italy

\*These authors contributed equally to this work.

### ABSTRACT

The number of intestinal mast cells (MC) is increased in several types of colitis, but the mucosa of patients with chronic non-bloody diarrhea has not been studied. The current study sought to determine the relationship between MC counts and degranulation and the severity of symptoms in patients with chronic loose stools. Following a negative laboratory workup for the most common causes of chronic diarrhea, patients with chronic non-bloody loose stools were included in the study. Patients with macroscopic evidence of inflammation or organic disease were excluded after endoscopy with biopsies. Biopsies from the 179 patients in the study were stained with hematoxylin and eosin and anti-CD117 c-kit antibodies. Immunohistochemistry was used to assess the degree of MC degranulation. Out of the 179 patients, 128 had normal histologic findings suggestive of irritable bowel syndrome and were used as controls. Twenty-four presented with abnormally high MC counts ( $\geq 40$  MC x HPF), 23 with  $\geq 20$  intraepithelial lymphocytes x HPF suggesting lymphocytic colitis, and 4 had both ( $\geq 40$  MC and  $\geq 20$  intraepithelial lymphocytes x HPF). In the patients with high MC counts, figures were significantly higher in the right colon versus the left colon ( $p=0.016$ ), but degranulation did not differ in the right versus the left colon ( $p=0.125$ ). No age or sex-related difference was observed ( $p=0.527$  and  $p=0.859$  respectively). The prevalence of abdominal pain and bloating did not differ in the three groups ( $p=0.959$  and  $p=0.140$ , respectively). Patients with lymphocytic colitis ( $p=0.008$ ) and those with high MC count ( $p=0.025$ ) had significantly higher evacuation rates compared to controls. There was no difference between these two groups ( $p=0.831$ ). Mast cell degranulation was not associated with the number of evacuations, abdominal pain, or bloating ( $p=0.51$ ;  $p=0.41$ ;  $p=0.42$ , respectively). The finding that a significantly higher number of evacuations was linked to increased MC in the colonic mucosa of a subset of patients with otherwise normal laboratory and endoscopic findings suggests that "mastocytic colitis" may be a new clinical-pathological entity responsible for chronic non-bloody diarrhea. Prospective studies with a larger number of patients, as well as endoscopic and histological follow-up, are needed to confirm this hypothesis.

**Key words:** Microscopic colitis; mast cell; mastocytic colitis; lymphocytic colitis; chronic diarrhea.

**Correspondence:** Giovanni Latella, Gastroenterology Unit, Department of Life, Health and Environmental Sciences, University of L'Aquila, Piazza S. Tommasi 1 - Coppito, 67100 L'Aquila, Italy. Tel. +39.0862.434735. E-mail: giovanni.latella@univaq.it

**Contributions:** FV, NC, MM, AC, GL, endoscopic examination performing, biopsy samples collection; TT, SP, RS, AV, performing of pathological and immunohistochemical examination of the specimens; SN, statistical analysis; FV, manuscript drafting, figures preparation; GL, study concept, supervision, manuscript drafting and critical revision. All the authors read and approved the final version of the manuscript and agreed to be accountable for all aspects of the work.

**Conflict of interest:** The authors declare that they have no competing interests, and all authors confirm accuracy.

**Funding:** No financial support was received for this study.

**Ethical approval:** The study was performed with the Institutional Review Board's approval (Prot. N. 49353/2018). Written informed consent was obtained from all patients included in the present study.

## Introduction

Chronic diarrhea is defined as 3 or more liquid or loose stools exceeding 200 g/day, for more than 4 weeks.<sup>1</sup> However, as precise quantification proves difficult in clinical practice, the British Society of Gastroenterology proposed as a pragmatic definition of chronic diarrhea the persistent alteration of stool consistency (types 5-7 of the Bristol stool scale) and increased frequency, for more than 4 weeks.<sup>2</sup>

Regardless of definition, the prevalence of chronic diarrhea is high, affecting up to 5-10% of the adult population.<sup>3</sup> The majority of cases are caused by bloodless diarrhea, and the cause varies depending on country, age, and socioeconomic status.<sup>2</sup> Irritable bowel syndrome (IBS), malabsorption syndromes (including celiac disease), parasites, chronic infections, and a subset of chronic inflammatory bowel diseases (IBD) are the most common causes in developed countries.<sup>1,3</sup> Ten to twenty percent of cases are affected by microscopic colitis.<sup>4</sup> Non-bloody diarrhea is associated with eosinophilic colitis in a minority of cases.<sup>5</sup>

A novel clinical-pathological condition, known as mastocytic enterocolitis, was described in 2006 by Jakate.<sup>6</sup> Diagnosis was based on the presence of chronic diarrhea and abdominal pain, with normal endoscopic appearance of the colonic mucosa, associated with an increased number of intestinal mast cells (MC), assessed by specific immunohistochemical staining in biopsy specimens.<sup>6</sup> Subsequent studies supported this hypothesis,<sup>7-13</sup> although the increased mast cells could merely represent one of the potential mediators of inflammation.<sup>14</sup>

Unlike other forms of microscopic colitis, mastocytic enterocolitis responds to treatment with antihistamines and/or MC membrane stabilizers.<sup>6</sup> Two main subtypes of MC have been identified on the base of their protease content: those containing tryptase, chymase, and carboxypeptidase (MC<sub>TC</sub>) and those containing tryptase only (MC<sub>T</sub>).<sup>15</sup> A third phenotype, synthesizing tryptase and carboxypeptidase A3, but not chymase, has also been described in the airway epithelium of asthmatic patients and esophageal biopsies of patients affected by eosinophilic esophagitis.<sup>16</sup> The distribution of these subtypes in the intestinal wall is not homogeneous, as MC<sub>T</sub> are mostly observed in the mucosa, and MC<sub>TC</sub> in the submucosa. Following activation, they all synthesize inflammatory mediators, which regulate the permeability of intestinal and vascular epithelium, electrolyte exchanges, and blood flow, and take part in the defense against bacterial, viral, and parasitic infections.<sup>17,18</sup> They also influence tissue remodeling, leading to fibrosis and scarring, and through neuroimmune interaction regulate peristalsis and pain.<sup>17,19-21</sup> The increase of MC in the intestinal mucosa is well-known in systemic mastocytosis<sup>22,23</sup> and is often associated with diarrhea and abdominal pain. The role of MC in other pathologic conditions is less clear, but they are likely involved in IBS, IBD, microscopic colitis, and eosinophilic colitis.<sup>12,19,24-27</sup>

In animal models of colitis, the activation of intestinal MC results in flare-ups of inflammation.<sup>28</sup> MC and their mediators, located within the muscle layer, near stenotic segments are likely involved in the fibrotic process in Crohn's disease.<sup>21,29</sup> Increased numbers of MC have also been described in the *muscularis propria* of fibro-stenotic areas, in ulcerative colitis.<sup>27,30</sup> Granules containing chemotactic mediators favor eosinophilic infiltration in the intestine and trigger the inflammatory process in eosinophilic colitis.<sup>25</sup> Increased numbers of MC, and high levels of extracellular tryptase, a marker of degranulation, have been reported as well in collagenous colitis.<sup>26</sup> IBS represents the most common cause of chronic non-bloody diarrhea in western countries, but the occurrence and role of MC in IBS are debated. Thus, MC in biopsies from IBS-D patients is not routinely investigated.

The present study was thus aimed at assessing the number, and

the degree of degranulation, of MC in the colonic biopsies of patients chronically presenting with loose stools. The relationship of MC counts with the severity of diarrhea and abdominal pain was also investigated. Differences in patients with lymphocytic colitis (LC) and healthy control patients were also sought.

## Materials and Methods

All adult patients (defined as age >18 years) undergoing colonoscopy for chronic bloodless diarrhea from January 2018 to January 2020 at the Gastroenterology, Hepatology, and Nutrition Unit of the San Salvatore Hospital, L'Aquila, Italy, were included in the study. The study was performed with the Institutional Review Board's approval (Prot. n. 49353/2018). All clinical investigations were conducted according to the principles laid down in the Declaration of Helsinki.

Chronic diarrhea was defined according to the British Society of Gastroenterology, as the presence of persistently loose stools for more than 4 weeks.<sup>2</sup> Laboratory tests, including blood count, ESR, PCR, TSH, bacteriological (*Salmonella* spp, *Shigella dysenteriae*, *Campylobacter jejuni*, *Yersinia enterocolitica* and pathogenic *Escherichia coli*), and parasitological (amoeba included) stool examination, fecal toxins of *Clostridium difficile*, fecal calprotectin, total IgE, total IgA, anti-transglutaminase IgA, and anti-endomysial antibodies, glucose and lactose breath test and nickel patch test were performed before endoscopy to exclude specific organic disease. A colonoscopy was performed in conscious sedation (midazolam 2-5mg iv), after bowel preparation with a polyethylene glycol solution.

Patients that did not complete the endoscopic examination or with poor colonic cleaning (Boston Bowel Preparation Score 0-1 in a single segment) were excluded, as well as those presenting with macroscopic evidence of inflammation (edema/hyperemia, aphthae, petechiae, erosions, ulcers). Patients affected by IBD, cancer, extensive diverticulosis, and systemic mastocytosis were excluded.

The internal protocol of our Center for patients with diarrhea requires the collection of three biopsies in the right colon and three biopsies in the left colon. Biopsies were stored in 10% formalin and carried within 2 h to the Department of Pathology. Biopsies were processed for routine histological examination and 5 µm thick sections were stained with hematoxylin-eosin which allowed defining the histological features of the colonic mucosa and, if present, the type of inflammatory infiltrate in the lamina propria (Figure 1).

The presence of an inflammatory infiltrate in the mucosa and the submucosa was sought and microscopic colitis was diagnosed according to the latest guidelines.<sup>4</sup> When present, MC was subsequently investigated using the immunostaining technique with the anti-CD117 c-kit antibody (Dako Denmark A/S, Glostrup, Denmark; Polyclonal Rabbit anti-human CD117, c-kit – cod. n. A4502).

The count was performed at a 40x magnification in 5 different fields selected in the area with the highest density of inflammatory cells. Only intact MC with visible nuclei and dark-colored cytoplasm were counted. Mastocytic colitis was diagnosed in the presence of  $\geq 40$  MC x high-power field (HPF), as the count of MC in controls was reported to be  $24 \pm 9$  MC x HPF (Figure 2).<sup>9</sup>

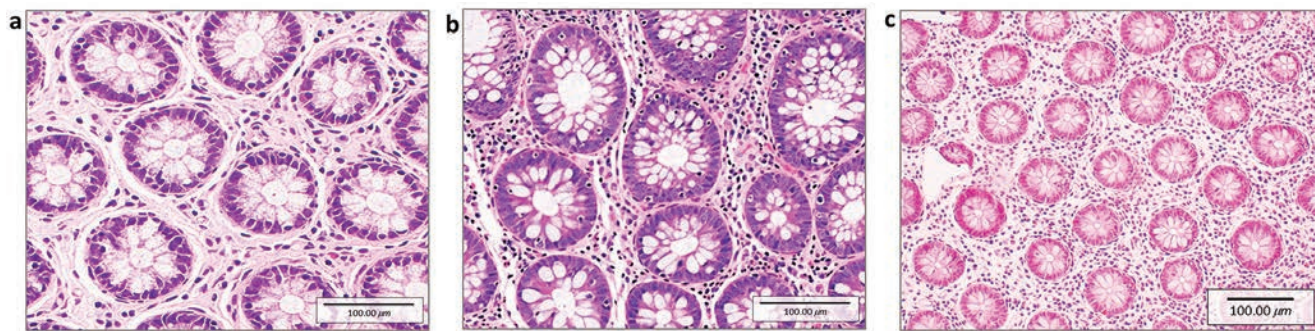
The degree of degranulation of MC, evaluated by immunohistochemistry (Dako Denmark A/S; FLEX Monoclonal Mouse Anti-Human Mast Cell Tryptase, Clone AA1, Ready-to-Use antibody – cod. n. IR640), was also recorded.

Less than 50% x HPF degranulated cells, associated with light staining intensity were considered as low- or negative for degranu-

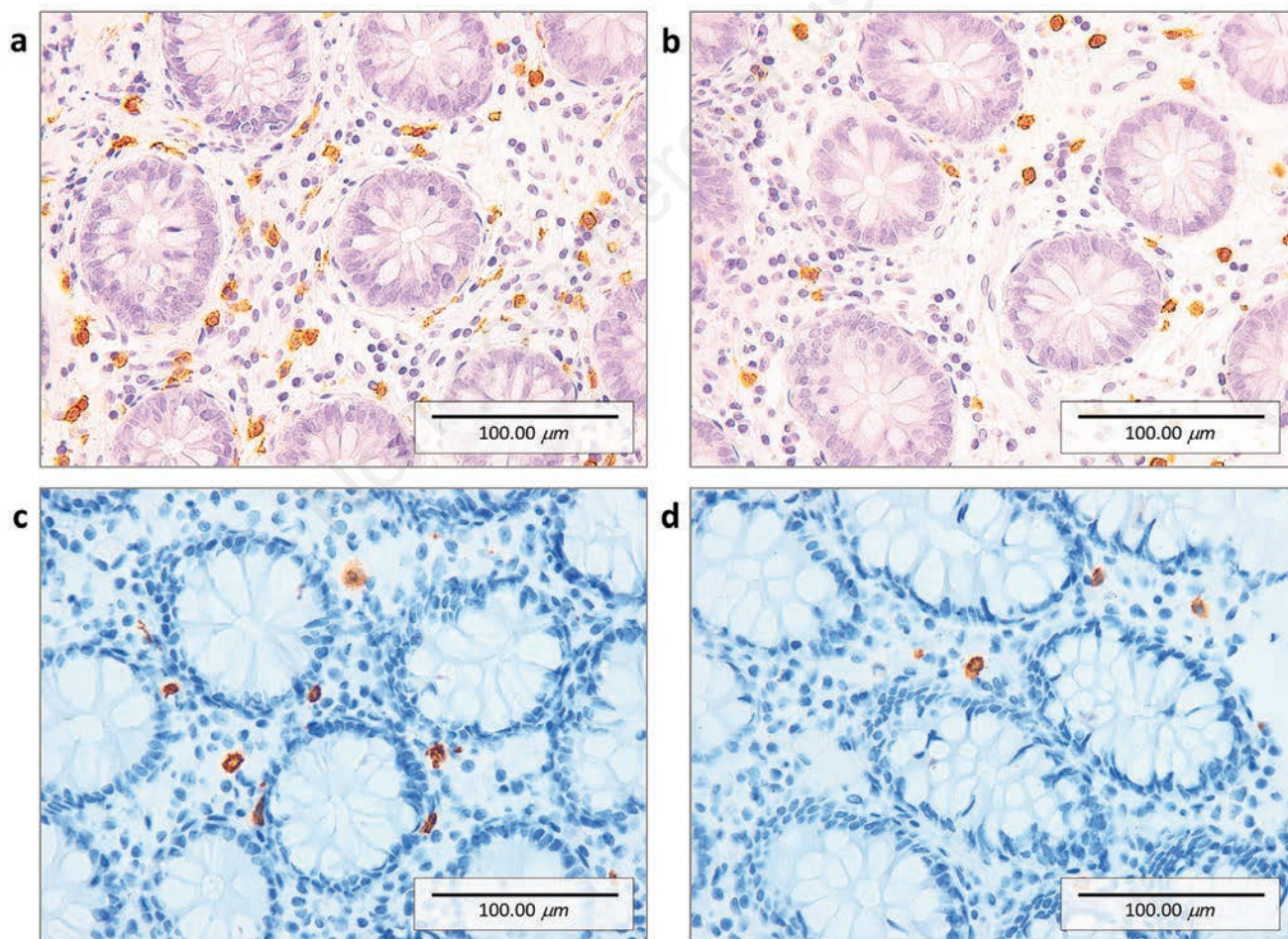
lation (Trip -). A percentage  $\geq 50\%$  x HPF of degranulated cells, irrespective of mild, moderate, or severe staining intensity, was considered as high degree/positive for degranulation (Trip +) (Figure 3).

### Statistical analysis

The SAS statistical package (version 9.4, 2002-2012 by SAS Institute Inc., Cary, NC, USA) was used for statistical analysis. Data were compared using the Wilcoxon Rank Sum Test for con-



**Figure 1.** Hematoxylin-eosin staining. a) Colonic mucosa of patients without significant histological alterations (40x) and considered as controls. b) Colonic mucosa of patients with an increased number of intraepithelial lymphocytes ( $>20$  lymphocytes/100 enterocytes) and with an increase in the inflammatory infiltrate in the lamina propria (40x), defining lymphocytic colitis. c) Colonic mucosa of a patient with a marked increase in the number of mast cells ( $>40$  x HPF) and increased inflammatory infiltrate in the lamina propria, but normal intraepithelial lymphocytes (20x), tentatively classified as “mastocytic colitis”.



**Figure 2.** CD117 immunostaining (40x). Only intact mast cells (MC) with visible nuclei and dark-colored cytoplasm were counted. Mastocytic colitis was diagnosed in the presence of  $>40$  MC x HPF. MC in the right (a) and left colon (b) of patients with MC x HPF  $>40$ . MC in the right (c) and left colon (d) of patients with MC x HPF  $<40$ .

tinuous variables and Chi-Squared Test or Fisher's Exact test, as appropriate, for dichotomous variables. Spearman's nonparametric correlation was used to evaluate the degree of relationship between variables. A p-value  $\leq 0.05$  was considered statistically significant.

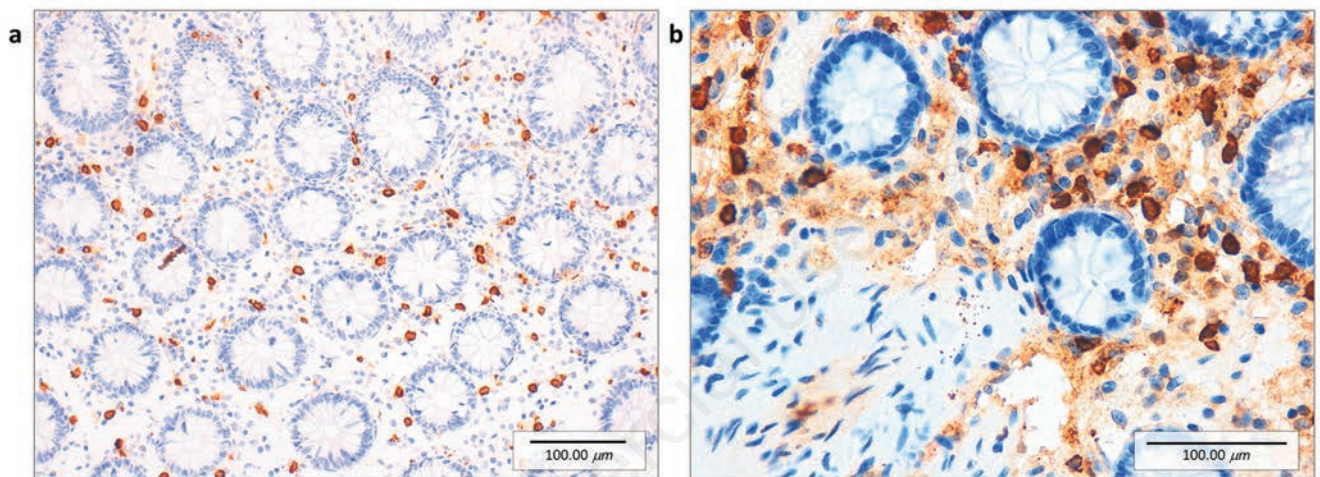
## Results

One-thousand-six-hundred-forty-six patients underwent colonoscopy during the study period. Two-hundred-sixty-one patients with chronic bloodless diarrhea as previously defined met the inclusion criteria, but 55 were excluded due to incomplete bowel preparation (20) or denied consent to participate in the study

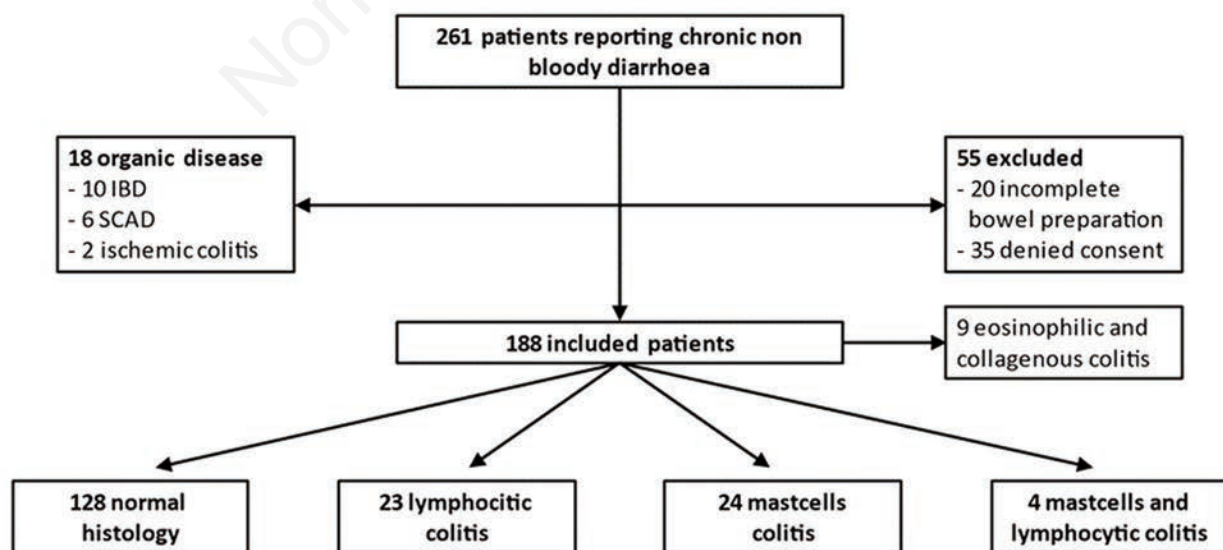
(35). Despite macroscopically normal colonic mucosa, 18 more patients were excluded due to diagnosis of colonic organic disease (10 IBD, 6 segmental colitis associated with diverticulosis, 2 ischemic colitis) in previous examinations.

One-hundred-eighty-eight patients with chronic non-bloody diarrhea were thus included in the present study (Figure 4). One-hundred and twenty-eight had normal histological findings (not fulfilling the diagnostic criteria for microscopic or eosinophilic colitis, less than 40 MC x HPF and less than 20 intraepithelial lymphocytes x HPF) and were labeled as controls (54 males and 74 females, average age 55 years, 19-86).

Nine patients affected by eosinophilic or collagenous colitis were excluded from the final analysis, as the small sample size prevented adequate statistical power.



**Figure 3.** Tryptase immunostaining. a) Tryptase negative: degranulated mast cells <50% with mild intensity (20x). b) Tryptase positive: degranulated mast cells >50% with high intensity (40x).



**Figure 4.** Overview of the inclusion process of patients in the study.

Based on the histopathological findings, the 51 remaining patients were classified into three case groups (Figure 4 and Table 1).

- twenty-four patients, 16 male, and 8 women, with an average age of 52 years (20-76), presented with  $\geq 40$  MC x HPF, and were tentatively classified as affected by “mastocytic colitis”;
- twenty-three patients, 10 men, and 13 women, with an average age of 50 years (20-81) presented with more than  $\geq 20$  intraepithelial lymphocytes x HPF, and were classified as LC;
- four women, average age of 64 years (51-72), had both  $\geq 40$  MC and  $\geq 20$  intraepithelial lymphocytes x HPF.

**MC number and distribution**

The mean number of MC in the biopsy specimens was  $44.82 \pm 8.39$  SD in the mastocytic colitis group,  $16.33 \pm 12.19$  in the LC group, and  $16.61 \pm 11.42$  SD in the control population (Figure 5).

In the patients with mastocytic colitis, considering the median age of 53 years in our series as a cut-off, no difference in the number of MC was observed between younger or older patients ( $44.2 \pm 10.0$  vs  $46.4 \pm 8.6$ ,  $p=0.527$ ). Similarly, the number of MC was comparable in male (16) and female (12) patients ( $45.9 \pm 10.2$

vs  $43.8 \pm 6.9$ ,  $p=0.859$ ). The number of MC was instead significantly higher in the right colon vs the left colon ( $47.68$  vs  $39.86$ ;  $p=0.016$ ). Despite a trend toward increased degranulation in the right colon, the difference versus the left colon was non-significant (Trip+ 19 vs 9;  $p=0.125$ ).

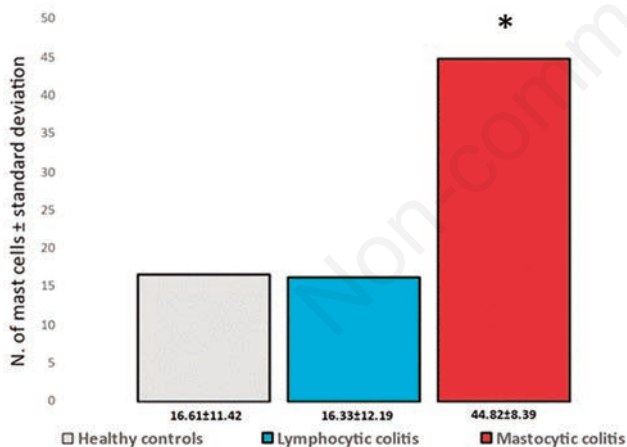
**Clinical presentation**

The prevalence of abdominal pain did not differ in the three different groups of patients ( $p=0.959$ ), as well as bloating ( $p=0.140$ ) (Table 2). A significant difference in the number of evacuations was indeed observed between patients with LC and controls ( $2.8 \pm 1.1$  vs  $2.1 \pm 1.6$ ; median 3 vs 1;  $p=0.008$ ) (Figure 6). The same proved true comparing those with mastocytic colitis and controls ( $2.9 \pm 1.8$  vs  $2.1 \pm 1.6$ ; median 3 vs 1;  $p=0.025$ ). No difference was observed between the LC and mastocytic colitis ( $p=0.831$ ). The number of evacuations, abdominal pain, and bloating were not associated with increased mast cell degranulation ( $p=0.51$ ;  $p=0.41$ ;  $p=0.42$  respectively).

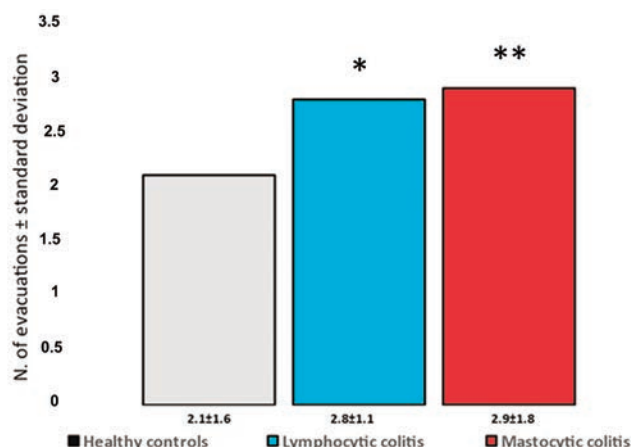
The patient’s history of medication use was heterogeneous and not different between the three groups of patients. The medications

**Table 1. Patient characteristics.**

	Normal histology	Lymphocytic colitis	Mast cell colitis	Lymphocytic and mast cell colitis
Patients (179)	128	23	24	4
Men (80)	54	10	16	0
Women (99)	74	13	8	4
Age in years (54)	55 (19-86)	50 (20-81)	52 (20-76)	64 (51-72)



**Figure 5.** Mean number of mast cells observed in the biopsy specimens of controls, patients affected by lymphocytic colitis, and patients with mastocytic colitis; \* $p=0.0003$  vs controls and lymphocytic colitis.



**Figure 6.** Mean number of mast cells observed in the biopsy specimens of controls, patients affected by lymphocytic colitis, and patients with mastocytic colitis; \* $p=0.0003$  vs controls and lymphocytic colitis.

**Table 2.** Number and % of patients reporting abdominal pain and bloating.

	Normal histology (128)	Lymphocytic colitis (23)	Mastocytic colitis (24)
Abdominal pain	65 (50.7%)	12 (52.2%)	10 (41.7%)
Bloating	35 (27.3%)	5 (21.7%)	10 (41.7%)

most frequently taken by the enrolled patients were proton pump inhibitors (4 healthy controls, 3 LC; 2 mastocytic colitis), non-steroidal anti-inflammatory drugs (5 healthy controls, 3 LC; 1 mastocytic colitis), antihypertensive drugs (7 healthy controls, 4 LC; 2 mastocytic colitis) and statins (6 healthy controls, 2 LC; 1 mastocytic colitis). Discontinuation of drugs did not significantly improve diarrhea, except in 3 healthy controls, 2 patients with LC and 1 with mastocytic colitis. No patients in the three groups developed IBD at follow-up (range 10-28 months). Controls were successfully treated with anti-diarrheal drugs (loperamide), and patients with LC were treated with budesonide with efficacy in 90% of cases. To better control diarrhea, mast cell stabilizers (sodium cromoglicate) associated with histamine H2 receptor antagonists (ranitidine or famotidine) and H1 receptor antagonists (levocetirizine or desloratadine) had to be added to the budesonide in 7 (29%) of patients with mastocytic colitis.

## Discussion

Identifying the cause of chronic diarrhea represents a challenging problem in clinical practice, as several diseases must be taken into consideration. When the absence of clearly identified etiologic factors is associated with normal endoscopic and histological findings, IBS is diagnosed.<sup>31</sup> Conversely, when normal endoscopy is associated with microscopic inflammation, the diagnosis of microscopic colitis is set, further subdivided into collagenous colitis and LC.<sup>4</sup>

The pooled overall prevalence of microscopic colitis increased over time, possibly about an aging population and the increased rate of biopsies taken in diarrheal patients.<sup>14</sup> Thus, the condition is at present diagnosed in 119/100,000 inhabitants (95% CI, 73-166), with a slight prevalence of LC over collagenous colitis.<sup>4</sup> Microscopic colitis is more frequent in females than in males,<sup>32</sup> and smoking and drugs are likely additional risk factors,<sup>33,34</sup> although a direct cause-effect relation is unproven.

Eosinophilic colitis and mastocytic enterocolitis have been proposed as further subsets of microscopic colitis.<sup>5,6</sup> While eosinophilic colitis is rather rare (2.1/100000 persons),<sup>35</sup> the prevalence of mastocytic colitis is largely unknown, as MC is not routinely sought by pathologists.<sup>14</sup>

The gastrointestinal tract hosts the largest MC population, mainly in the lamina propria of mucosa and in the submucosa.<sup>17</sup> MC represents 2-5% of the mononuclear cells of the lamina propria of the gastrointestinal tract. Up to 13±3 MC x HPF are observed in the normal colonic mucosa,<sup>6</sup> but higher figures have also been reported (24±9 MC x HPF).<sup>9</sup> Following activation, MC degranulate, releasing proteases and inflammatory mediators, including histamine, serotonin, tryptase, chemokines, and cytokines.<sup>36</sup> MC increases visceral sensitivity and triggers abdominal pain, by releasing proteases and activating specific receptors<sup>37</sup> located near the nerve endings.<sup>38</sup>

Besides playing a role in immune and allergic reactions, MC favors diarrhea modulating intestinal motility<sup>39</sup> and stimulating the secretion of water, NaCl, bicarbonate, and mucus.<sup>18,40</sup> A clinically relevant role of MC in gastrointestinal diseases may thus be anticipated.

The data reported in this study support the hypothesis that an abnormally high number of MC in the colonic mucosa identifies a subset of patients presenting with chronic diarrhea. Several MCs exceeding 40 x HPF was not rare in the present series (28/179 patients) which suggests that the finding may be clinically relevant. The significantly increased number of bowel movements in patients with high MC versus controls, but not *versus* LC patients, is in keeping with this view. Noteworthy, as the current criteria for microscopic colitis, are not fulfilled, these patients would otherwise

be diagnosed as affected by IBS. Similarly to other subtypes of microscopic colitis, gender- and age-related differences in the distribution of MC have been reported in the past,<sup>7</sup> but this was not the case in our cohort, in line with data reported by Zare-Mirzaie *et al.*<sup>8</sup>

In early reports, no site-related difference in the number of MCs has been reported.<sup>8</sup> Conversely, in our series the number of MCs was higher in the right colon, compared to the left colon. This observation is however in contrast with data reported by Sethi *et al.*, showing higher figures of MC in the left colon.<sup>9</sup> The relatively small size of the series reported in the literature may account for the variance. Systematically taking biopsy specimens both in the right and left colon should be considered in these patients to help draw definitive conclusions. The degree of degranulation, rather than the number of MC, has been advocated for shaping the clinical features of mastocytic colitis, in keeping with studies in IBS, suggesting the role of these cells in favoring visceral hypersensitivity.<sup>39</sup> Our data do not support this view but the small number of patients in our series prevents drawing definitive conclusions.

The main limitations of the study include the relatively small number of patients enrolled in the study and the lack of endoscopic and histological follow-up, which was considered clinically unnecessary or in some cases not accepted by the patients themselves. Furthermore, the response to antihistamines or MC membrane stabilizers therapy was evaluated only in a small proportion of patients and their usefulness requires further investigations. However, an increased number of intestinal MC is present in more than 15% of patients reporting chronic bloodless diarrhea, associated with negative endoscopic findings. The figure is like that of patients who were diagnosed as affected by LC and suggests that mastocytic colitis is not rare.

Thus, gastrointestinal pathologists should be aware of this possibility and take into consideration the number of MC when examining the biopsy specimens of patients with chronic bloodless diarrhea, rather than defining the findings as normal, and labeling patients as affected by IBS. This is supported by the finding that a significantly higher number of evacuations was associated with increased MC in the colonic mucosa compared to controls but not *versus* LC. It is thus proposed that mastocytic colitis may be responsible for chronic diarrhea in a subset of patients currently classified as IBS using current criteria.

More research on larger groups of patients with chronic bloodless diarrhea, as well as clinical, endoscopic, and histological follow-up, are needed to support this hypothesis, as is a precise definition of the normal range of MC in colonic biopsies of healthy controls.

## References

- Schiller LR. Chronic diarrhea. *Gastroenterology* 2004;127:287-3.
- Arasradnam RP, Brown S, Forbes A, Fox MR, Hungin P, Kelman L, et al. Guidelines for the investigation of chronic diarrhoea in adults: British Society of Gastroenterology, 3rd edition. *Gut* 2018;67:1380-99.
- Singh P, Mitsuhashi S, Ballou S, Rangan V, Sommers T, Cheng V, et al. Demographic and dietary associations of chronic diarrhoea in a representative sample of adults in the United States. *Am J Gastroenterol* 2018;113:593-600.
- Miehlke S, Guagnozzi D, Zabana Y, Tontini GE, Kanstrup Fiehn AM, Wildt S, et al. European guidelines on microscopic colitis: United European Gastroenterology and European Microscopic Colitis Group statements and recommendations. *United European Gastroenterol J* 2021;9:13-37.
- Licari A, Votto M, Scudeller L, De Silvestri A, Rebuffi C,

- Cianferoni A, Marseglia GL. Epidemiology of nonesophageal eosinophilic gastrointestinal diseases in symptomatic patients: a systematic review and meta-analysis. *J Allergy Clin Immunol Pract* 2020;8:1994-2003.
6. Jakate S, Demeo M, John R, Tobin M, Keshavarzian A. Mastocytic enterocolitis increased mucosal mast cells in chronic intractable diarrhea. *Arch Pathol Lab Med* 2006;130:362-7.
  7. Park JH, Rhee PL, Kim HS, Lee JH, Kim YH, Kim JJ, Rhee JC. Mucosal mast cell counts correlate with visceral hypersensitivity in patients with diarrhea-predominant irritable bowel syndrome. *J Gastroenterol Hepatol* 2006;21:71-8.
  8. Zare-Mirzaie A, Lotfi M, Sadeghipour A, Haghi-Ashtiani M. Analysis of colonic mucosa mast cell count in patients with chronic diarrhea. *Saudi J Gastroenterol* 2012;18:322-6.
  9. Sethi A, Jain D, Roland BC, Kinzel J, Gibson J, Schrader R, Hanson JA. Performing colonic mast cell counts in patients with chronic diarrhea of unknown etiology has limited diagnostic use. *Arch Pathol Lab Med* 2015;139:225-32.
  10. Doyle LA, Sepehr GJ, Hamilton MJ, Akin C, Castells MC, Hornick JL. A clinicopathologic study of 24 cases of systemic mastocytosis involving the gastrointestinal tract and assessment of mucosal mast cell density in irritable bowel syndrome and asymptomatic patients. *Am J Surg Pathol* 2014;38:832-43.
  11. Akhavein AM, Patel NR, Muniyappa PK, Glover SC. Allergic mastocytic gastroenteritis and colitis: an unexplained etiology in chronic abdominal pain and gastrointestinal dysmotility. *Gastroenterol Res Pract* 2012;2012:950582.
  12. Capannolo A, Ciccone F, Latella G. Mastocytic enterocolitis and the role of mast cells in functional and inflammatory intestinal disorders: a systematic review. *Dig Dis* 2018;36:409-16.
  13. Capannolo A, Viscido A, Sollima L, Marinucci A, Coletti G, Pasetti A, et al. Mastocytic enterocolitis: Increase of mast cells in the gastrointestinal tract of patients with chronic diarrhea. *Gastroenterol Hepatol* 2017;40:467-70.
  14. Yen EF, Pardi DS. Review article: microscopic colitis – lymphocytic, collagenous and ‘mast cell’ colitis. *Aliment Pharmacol Ther* 2011;34:21-32.
  15. Irani AM, Bradford TR, Kepley CL, Schechter NM, Schwartz LB. Detection of MCT and MCTC types of human mast cells by immunohistochemistry using new monoclonal anti-tryptase and anti-chymase antibodies. *J Histochem Cytochem* 1989;37:1509-15.
  16. Dougherty RH, Sidhu SS, Raman K, Solon M, Solberg OD, Caughey GH, et al. Accumulation of intraepithelial mast cells with a unique protease phenotype in T(H)2-high asthma. *J Allergy Clin Immunol* 2010;125:1046-53.
  17. Albert-Bayo M, Paracuellos I, González-Castro AM, Rodríguez-Urrutia A, Rodríguez-Lagunas MJ, Alonso-Cotoner C, et al. Intestinal mucosal mast cells: key modulators of barrier function and homeostasis. *Cells* 2019;8:135.
  18. Crowe SE, Luthra GK, Perdue MH. Mast cell mediated ion transport in intestine from patients with and without inflammatory bowel disease. *Gut* 1997;41:785-92.
  19. Gelbmann CM, Mestermann S, Gross V, Köllinger M, Schölmerich J, Falk W. Strictures in Crohn’s disease are characterized by an accumulation of mast cells colocalised with laminin but not with fibronectin or vitronectin. *Gut* 1999;45:210-7.
  20. Xu X, Weksler-Zangen S, Pikarsky A, Pappo O, Wengrower D, Bischoff SC, et al. Mast cells involvement in the inflammation and fibrosis development of the TNBS-induced rat model of colitis. *Scand J Gastroenterol* 2002;37:330-7.
  21. Xu X, Rivkind A, Pikarsky A, Pappo O, Bischoff SC, Levi-Schaffer F. Mast cells and eosinophils have a potential profibrogenic role in Crohn disease. *Scand J Gastroenterol* 2004;39:440-7.
  22. Sokol H, Georgin-Lavialle S, Grandpeix-Guyodo C, Canioni D, Barete S, Dubreuil P, et al. Gastrointestinal involvement and manifestations in systemic mastocytosis. *Inflamm Bowel Dis* 2010;16:1247-53.
  23. Hamilton MJ, Hornick JL, Akin C, Castells MC, Greenberger NJ. Mast cell activation syndrome: a newly recognized disorder with systemic clinical manifestations. *J Allergy Clin Immunol* 2011;128:147-52.
  24. Gao J, Xiong T, Grabauskas G, Owyang C. Mucosal serotonin reuptake transporter expression in irritable bowel syndrome is modulated by gut microbiota via mast cell-prostaglandin E2. *Gastroenterology* 2022;162:1962-74.
  25. Awad H, Sfaira A, Abu Osba Y, Shahin M, Al-Asa’d Y, Sbeih N, et al. Mast cell numbers in primary eosinophilic colitis are significantly higher than in secondary tissue eosinophilia and normal control: a possible link to pathogenesis. *Iran J Immunol* 2021;18:220-9.
  26. Chi Z, Xu J, Saxena R. Increased mast cell counts and degranulation in microscopic colitis. *Gastroenterol Res Pract* 2020;2020:9089027.
  27. Chen E, Chuang LS, Giri M, Villaverde N, Hsu NY, Sabic K, et al. Inflamed ulcerative colitis regions associated with MRG-PRX2-mediated mast cell degranulation and cell activation modules, defining a new therapeutic target. *Gastroenterology* 2021;160:1709-24.
  28. Hamilton MJ, Sinnamon MJ, Lyng GD, Glickman JN, Wang X, Xing W, et al. Essential role for mast cell tryptase in acute experimental colitis. *Proc Natl Acad Sci* 2011;108:290-5.
  29. Middel P, Reich K, Polzien F, Blaschke V, Hemmerlein B, Herms J, et al. Interleukin 16 expression and phenotype of interleukin 16 producing cells in Crohn’s disease. *Gut* 2001;49:795-803.
  30. Fox CC, Lazenburg AJ, Moore WC, Yardley JH, Bayless TM, Lichtenstein LM. Enhancement of human intestinal mast cell mediator release in active ulcerative colitis. *Gastroenterology* 1990;99:119-24.
  31. Carrasco-Labra A, Lytvyn L, Falck-Ytter Y, Surawicz CM, Chery WD. AGA Technical Review on the evaluation of functional diarrhea and diarrhea-predominant irritable bowel syndrome in adults (IBS-D). *Gastroenterology* 2019;157:859-80.
  32. Tong J, Zheng Q, Zhang C, Lo R, Shen J, Ran Z. Incidence, prevalence, and temporal trends of microscopic colitis: a systematic review and meta-analysis. *Am J Gastroenterol* 2015;110:265-76.
  33. Jaruvongvanich V, Poonsombudert K, Ungprasert P. Smoking and risk of microscopic colitis: a systematic review and meta-analysis. *Inflamm Bowel Dis* 2019;25:672-8.
  34. Yen EF, Yoo J, Ture A, Lapin B, Bianchi LK, Elton E, et al. Medication exposure and the risk of microscopic colitis: results from a prospective US trial. *Gastroenterology* 2017;152:S194.
  35. Mansoor E, Saleh MA, Cooper GS. Prevalence of eosinophilic gastroenteritis and colitis in a population-based study, from 2012 to 2017. *Clin Gastroenterol Hepatol* 2017;15:1733-41.
  36. Mukai K, Tsai M, Saito H, Galli SJ. Mast cells as sources of cytokines, chemokines, and growth factors. *Immunol Rev* 2018;282:121-50.
  37. Valdez-Morales EE, Overington J, Guerrero-Alba R, Ochoa-Cortes F, Ibeakanma CO, Spreadbury I, et al. Sensitization of peripheral sensory nerves by mediators from colonic biopsies of diarrhea-predominant irritable bowel syndrome patients: a role for PAR2. *Am J Gastroenterol* 2013;108:1634-43.
  38. Suzuki A, Suzuki R, Furuno T, Teshima R, Nakanishi M. N-

- cadherin plays a role in the synapse-like structures between mast cells and neurites. *Biol Pharm Bull* 2004;27:1891-4.
39. Barbara G, Stanghellini V, De Giorgio R, Cremon C, Cottrell GS, Santini D, et al. Activated mast cells in proximity to colonic nerves correlate with abdominal pain in irritable bowel syndrome. *Gastroenterology* 2004;126:693-702.
40. Castro GA, Harari Y, Russell D. Mediators of anaphylaxis-induced ion transport changes in small intestine. *Am J Physiol* 1987;253:G540-8.

Non-commercial use only

---

Received for publication: 22 July 2022. Accepted for publication: 10 November 2022.

This work is licensed under a Creative Commons Attribution-NonCommercial 4.0 International License (CC BY-NC 4.0).

©Copyright: the Author(s), 2022

Licensee PAGEPress, Italy

*European Journal of Histochemistry* 2022; 66:3499

doi:10.4081/ejh.2022.349

*Publisher's note: All claims expressed in this article are solely those of the authors and do not necessarily represent those of their affiliated organizations, or those of the publisher, the editors and the reviewers. Any product that may be evaluated in this article or claim that may be made by its manufacturer is not guaranteed or endorsed by the publisher.*