



European Journal of Histochemistry

SUPPLEMENTARY MATERIAL

DOI: [10.4081/ejh.2022.3563](https://doi.org/10.4081/ejh.2022.3563)

Combination of tolvaptan and valsartan improves cardiac and renal functions in doxorubicin-induced heart failure in mice

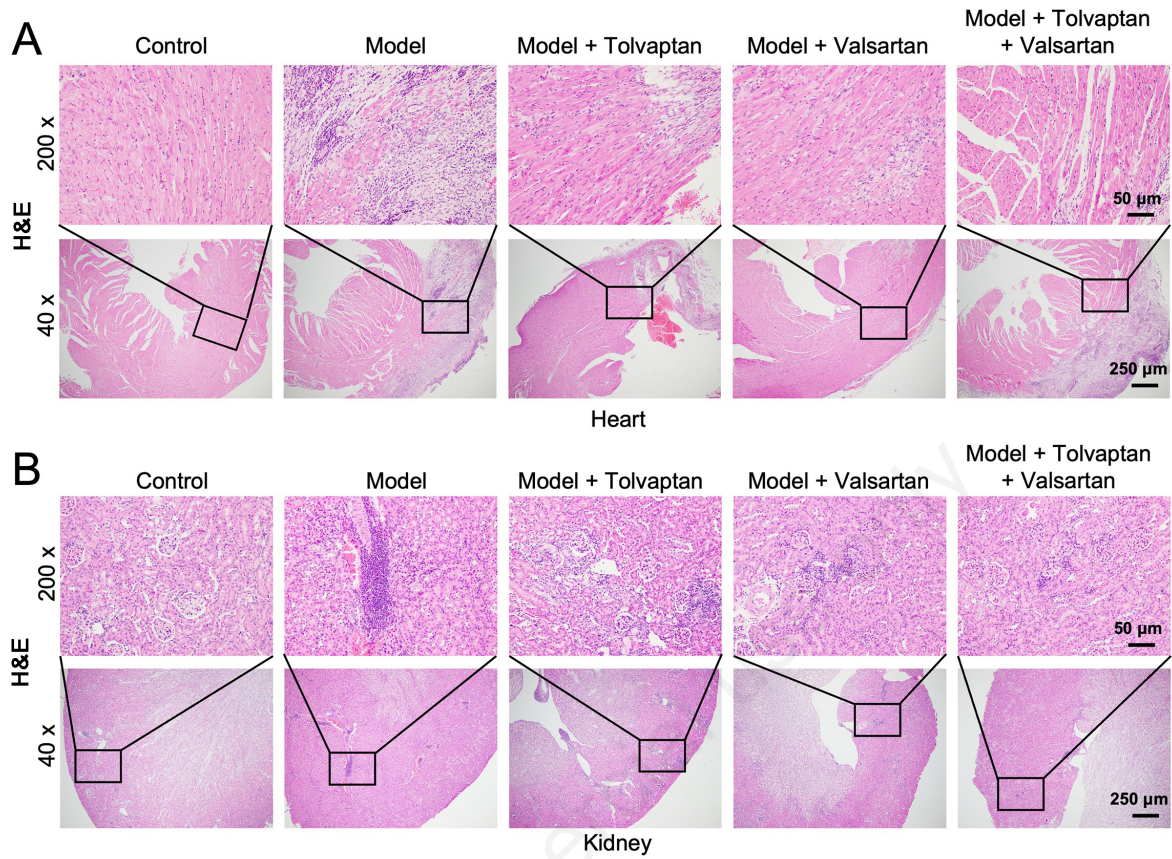
Fengqin Yan, Hong Zhu, Yingxia He, Qinqin Wu, Xiaoyu Duan

Department of General Practice, The Central Hospital of Wuhan, Tongji Medical College, Huazhong University of Science and Technology, Wuhan, Hubei, China

Correspondence: Hong Zhu, Department of General Practice, The Central Hospital of Wuhan, Tongji Medical College, Huazhong University of Science and Technology, 26 Shengli Street, Jiangan District, Wuhan, Hubei 430014, China. E-mail: zhuhong_zh53@126.com

Key words: Heart failure; renal dysfunction; tolvaptan; valsartan.

Supplementary Figure 1. H&E staining analysis was used to evaluate the pathological changes in heart and kidney tissues of mice. Magnification, 40 x and 200 x.



Supplementary Figure 2.

The collagen deposition in heart and kidney tissues of mice were determined by Masson staining assay. Magnification, 40 x and 200 x.

